



## Potential Risk Factors of Radiocarpal Stiffness Associated with Distal Radius Fractures

Sharif Md. Musa<sup>1\*</sup>, Erfanul Huq Siddiqui<sup>1</sup>, Mohammad Sazzad Hossain<sup>1</sup>, Sheikh Forhad<sup>1</sup>, A. K. Al Miraj<sup>2</sup>, Mohammad Al Mamun<sup>3</sup>

<sup>1</sup>Assistant Professor, Department of Orthopaedic Surgery, Bangabandhu Sheikh Mujib Medical University (BSMMU), Dhaka, Bangladesh

<sup>2</sup>Research Assistant, Department of Vascular Surgery, Bangabandhu Sheikh Mujib Medical University (BSMMU), Dhaka, Bangladesh.

<sup>3</sup>Assistant Professor, Department of Cardiology, Bangabandhu Sheikh Mujib Medical University (BSMMU), Dhaka, Bangladesh

### OPEN ACCESS

**\*Corresponding Author**  
Sharif Md. Musa

Assistant Professor,  
Department of Orthopaedic  
Surgery, Bangabandhu Sheikh  
Mujib Medical University  
(BSMMU) Dhaka, Bangladesh

Received: 04-09-2024

Accepted: 02-12-2024

Available online: 06-12-2024



©Copyright: IJMPR Journal

### ABSTRACT

**Introduction:** One of the most common fractures is the distal radius fracture in all the age groups. Among Distal radius fractures, Radiocarpal stiffness is one of the worst complications encountered. This study is to record the incidence and potential risk factors of radiocarpal stiffness associated with distal radius fractures. **Method:** This is a retrospective study which includes 60 patients diagnosed with distal radius fracture who underwent volar plate fixation. Patient's details such as basic data, radiological data and postoperative data were documented. The incidence of Radiocarpal joint stiffness during postoperative follow-ups were recorded and factors associated were determined. **Result:** This study comprised a total of 60 individuals who had their distal radius volar plate fixation. Multiple variables such as preoperative swelling, type of fracture (Intra-articular or Extra-articular), type of fixation (with or without k-wire), post-operative radiological changes pertaining to parameters such as volar tilt, Radial inclination and ulnar variance, rehabilitation was correlated with the incidence of Radiocarpal joint stiffness in distal radius fractures. **Conclusion:** Factors such as intra-articular extension, preoperative severe swelling, use of additional k-wire, unsatisfied volar tilt, improper rehabilitation is associated with a higher incidence of radiocarpal joint stiffness in patients with distal radius fracture. Re-operative risk notification and postoperative precautions are necessary for relevant patients.

**Keywords:** Distal radius, radiocarpal joint, stiffness, volar plating.

### INTRODUCTION

Distal radius fractures (DRFs) are the most common fractures of the upper limb and the most common fractures overall in individuals younger than 75 years [1, 2]. As a common injury, it account for approximately one sixth of all fractures in emergency departments [3, 4], and both conservative treatment and surgical procedure have been used to treat it [5-7]. For unstable fractures, surgery can provide improved radiologic parameters and better functional outcomes at an early stage of treatment. As the most common form of internal fixation, volar locking plate is widely used in the treatment of unstable DRFs. Patients could have an earlier return to normal activities with the reliable fixation of volar locking plate [8-10]. As described earlier distal radius fracture accounts around one sixth of all the patients reporting to emergency department [11, 12]. It can be treated both conservatively and surgically according to the fracture type [13-15]. For unstable fracture, volar plating is the most commonly used modality as it provides improved radiological parameter and better functional outcome as compared with conservative management. With reliable fixation, patients could return to normal functions early. The main goal of the internal fixation is to obtain pain free motion, disability and to reduce early degenerative changes. The main goal of treatment is obtaining sufficient pain-free motion, allowing early return to activities and minimizing the risk for future degenerative changes or disability. However, even with surgical treatment, radiocarpal joint stiffness (RJS) is a common postoperative complication following DRFs, which greatly

influence patients' normal function [16, 17]. Previous studies have investigated many postoperative complications following DRFs, such as tendon spontaneous rupture [18, 19], loss of reduction [20, 21], injury of triangular fibrocartilage complex [22], or wrist pain [23, 24]. To the best of our knowledge, no studies have been reported about postoperative RJS. Even with surgical management complications such as tendon rupture, loss of reduction, triangular fibrocartilage complex, wrist pain or radiocarpal joint stiffness is seen out of which radiocarpal stiffness which of much significance. Though it is important to study these complications we have only very less studies. In this study, we analyse the distal fracture cases who underwent volar plating. The goal of this study is to track the occurrence of postoperative RJS in patients after a 6- month follow-up period, as well as the possible risk factors for stiffness.

## Materials and Methods

Total sixty (60) patients were reviewed in this study from the month of January 2023 to March 2024 who have had distal radius fracture at Department of Orthopaedic Surgery, Bangabandhu Sheikh Mujib Medical University (BSMMU) Dhaka, Bangladesh. The inclusion criteria were radiologically confirmed closed distal radius fracture in adults treated with volar locking plate fixation. Ipsilateral upper limb injury, bilateral distal radius fracture, previous distal radius fracture, open fracture or neurovascular injury were the exclusion criteria for this study. Informed and written consent were obtained in order to store the patient information in the database for study purpose. This study was research and ethical committee after which it has been registered.

## Data Collection

Radiographic data, basic patient data and post-operative data were evaluated to recognise the associated factors. Age, gender and pre-operative swelling, habits, concomitant disease were the basic data collected. The swelling was considered slight if the skin texture is preserved, if it is not preserved then it is considered as severe. Fracture type, volar tilt, ulnar variance, radial inclination were the parameters in radiographic data which are measured at the 6 month follow up. Intra articular and extra articular types are the fracture types included in this study. A lateral view x-ray of the involved wrist is used to measure the volar tilt whereas in the anteroposterior view the radial inclination. Ulnar variance is also a parameter to be measured in the anteroposterior view x-ray of the wrist. Wrist mobilisation exercises were started by the surgeons in accordance with the rate of fracture healing, which is the ideal postoperative rehabilitation. Those patients who followed the advice given by the surgeon were considered to have done proper rehabilitation otherwise there were considered as improper with postoperative wrist rehabilitation. Wrist range of motion is measured considering the flexion- extension movement of the wrist as it is the most common movement at wrist. This range is measured using goniometer and it is considered as radiocarpal joint stiffness if the ROM is less than half of that in the contralateral wrist.

## Treatment and Follow-Up

The patients included in this study were performed open reduction and internal fixation for closed distal radius fracture with volar locking plating after regional or general block. All the patients included. In this study were operated using standard volar approach only. After exposure of the distal radius fracture site, open reduction procedure was attempted first, and volar locking plating with or without Kirschner wire was used to fix it. The surgeries were performed by five chief doctors only and the type of plate, screw configurations, surgical approach were decided by the operating surgeons only. Few surgeons used the help of plaster of paris after surgery, but the stability provided by the locking plate is usually sufficient to allow early controlled range of motion exercises. Elbow, shoulder and finger movements were started at post-operative day zero. The follow up was at 2, 4, 6 weeks and 3, 6 months. It is only at the 6<sup>th</sup> month the range of movement at the radiocarpal joint was measured and recorded.

## Statistical Analysis

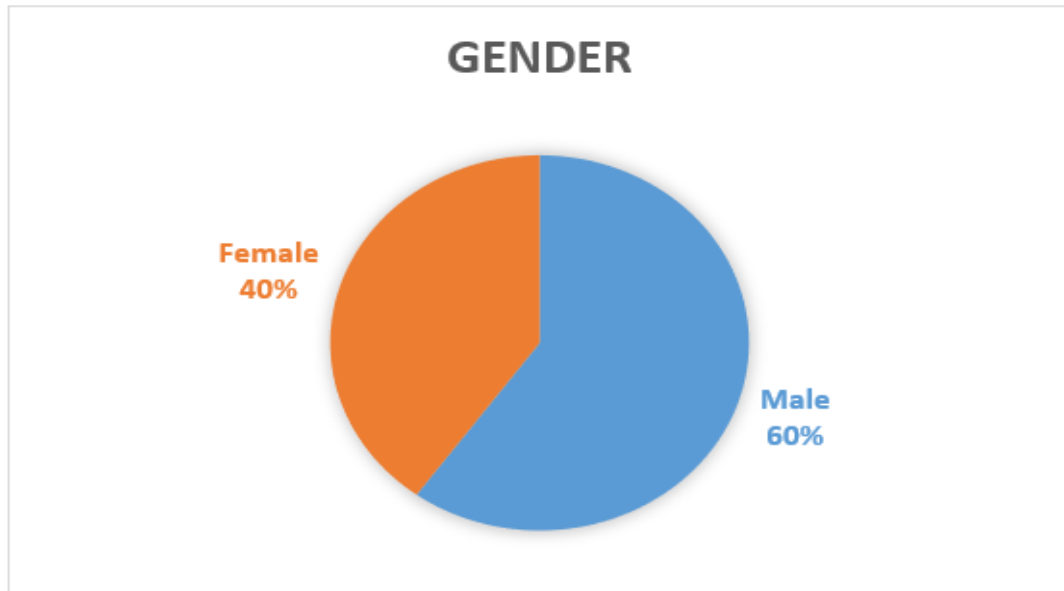
Statistical package for social sciences (SPSS) was used to perform the statistical analysis. For categorical variables frequencies and percentage and for continuous variables standard deviation were used to present the variables. The difference in frequencies of Nominal variables were identified using Fisher's exact test and independent sample t test or Mann-Whitney U test was used for numerical data. P values less than 0.05 were considered to be statistically significant whereas p value of <0.20 were considered potential variables.

## RESULTS

This study comprised a total of 60 individuals who had their distal radius volar plate fixed. Among these patients 36 (60%) patients were male and the remaining 24 (40%) patients were female (Fig-1), the mean age being 59.6 ranging from 49 to 79 years. Variables such as preoperative swelling (P value 0.03), type of fracture (Intra-articular or Extra-articular), type of fixation that is with or without k-wire (P value 0.37), post-operative radiological changes such as volar tilt (P value 0.03), Radial inclination and ulnar variance, rehabilitation (P value 0.01) were considered.

Out of 60 patients in this study 40 (66.7%) had slight and 20(33.3%) had severe preoperative swelling [Table 1]. Only one patient had postoperative complication of incision site infection. 24 (40%) patients had postoperative

radiocarpal joint stiffness and the rest 36 patients did not have. In the analysis of relation between patient basic data, radiological data and postoperative data with RJS, it is found that age, preoperative swelling, type of internal fixation, volar tilt, postoperative rehabilitation exercises potential risk factors which has a higher p value of <0.05 which is considered significant while gender, Comorbid, radial inclination, ulnar variance, postoperative infection were not. In further multi- logistic studies severe preoperative swelling, intra articular fracture, postoperative unsatisfied volar tilt and rehabilitation exercise were demonstrated to be strongly associated with Radiocarpal joint stiffness during serial follow-ups.



**Fig 1: Gender distribution**

**Table 1: Severity of pre-operative swelling**

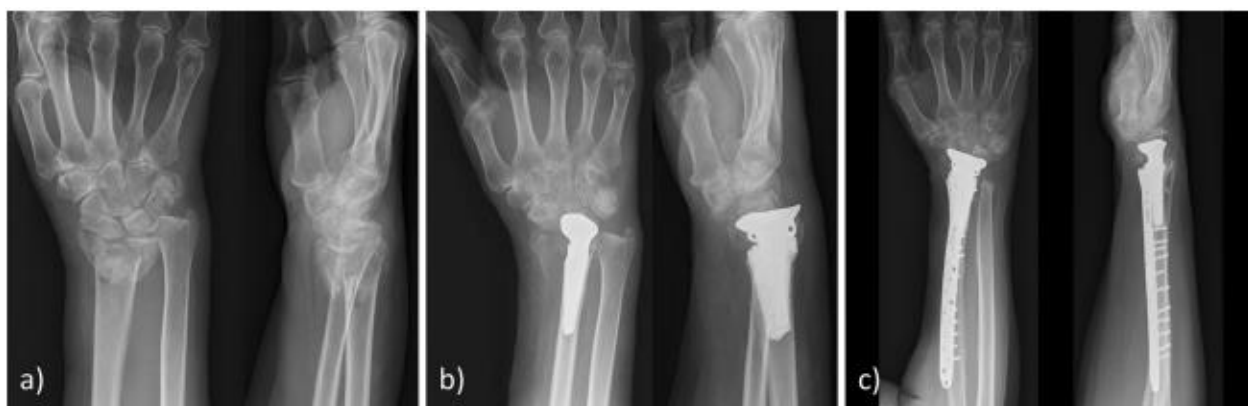Severity	N	%
Had Slight	40	66.7
Had Sever	20	33.3

**Table 2: Type of fracture Additional k-wire intra or extra articular.**

Fracture	N	%
extra- articular	40	66
intra-articular	20	34
<b>Additional k-wire</b>		
Casting k-wire	14	23.3
Splinting k-wire	46	76.7

A number of 40(66%) patients had extra- articular and 20(34%) patients had intra-articular fractures respectively. All the patient underwent open reduction and internal fixation with plate osteosynthesis, out of which for 14 (23.3%) patients were additionally treated with Kirschner wire. no patients were treated with additional casting/splinting (Table-2).

Open reduction was not acceptable and therefore a cemented hemiarthroplasty was performed from palmar. The first postoperative X-ray revealed radiocarpal dislocation requiring a secondary derotational osteotomy of the radius shaft with a Darrach procedure and a pronator quadratus muscle interposition transfer at the proximal ulna stump (Fig-2).



**Fig 2: A Radiograph of the initial fracture. b Radiocarpal dislocation after hemiarthroplasty from a palmar approach. Revision included derotational osteotomy with a Darrach procedure and a pronator quadratus interposition transfer. c Radiograph at the follow-up 16 months after revision**

## DISCUSSION

Patients with intra-articular fracture, pre-operative severe swelling, post-operative unsatisfied volar tilt, and improper rehabilitation exercise were demonstrated to be correlated with the incidence of RJS during follow-up. Therefore, risk notification before surgery and precautions after surgery are necessary for these patients. Our result showed that intra-articular fracture was associated with a diminished flexion/extension arc. Intra-articular fracture usually involves step-offs and gaps, which can result in residual articular incongruence even after surgical treatment. Identification of the variables associated with RJS may help surgeons in finding patients with higher risk for it and to decide the monitoring and follow up orders. This study is done with patients undergoing volar plating and revealed that the incidence of radiocarpal joint stiffness of 40% at 6 months of follow up. Intra articular fracture, pre-operative swelling(severe), unsatisfied volar tilt and most importantly improper rehabilitation post operatively were the variables associated with RJS. Even after surgical intervention there is step offs and gaps associated with intra articular fracture which can result in residual articular incongruence. Karnezis et al., [25] concluded that post-operative articular incongruity of  $\geq 1\text{mm}$  are associated with loss of wrist joint movements that is the dorsiflexion/palmar flexion. Radiological osteoarthritis may be as high as 9 folds with persistent intra articular incongruity. For a good postoperative wrist movement, we suggest that the articular surface and maintenance of congruity should be restored. Three parameters used to assess distal radius deformity are Volar tilt, radial inclination and radial shortening [26]. In certain cases, perfect anatomic reduction is very hard or almost impossible. If the residual dorsal angulation was  $\leq 10^\circ$ , radial inclination was  $\geq 15^\circ$ , and radial shortening with positive ulnar variance was  $< 3\text{ mm}$  was considered acceptable based on Grewal and MacDermid's [27] study. Postoperative volar tilt if unsatisfactory, is by itself an independent variable of RJS. Exaggerated dorsal angulation of more than 20 degrees may worsens functional outcome [28, 29]. For every 10 degree of dorsal angulation there is loss of approximately 3 degrees of volar flexion [30], 20 degrees may cause as close to 8-degree loss in volar flexion [31]. The around ligaments are damaged extensively in high energy injury and acts as an important prognostic indicator. Limb swelling can indirectly indicate the extend of the soft tissue damage. Rehabilitation exercise is important. Home exercises are as efficient as formal physiotherapy [32]. Studies were done to compare between early wrist exercise with late wrist exercise which concluded that no significant differences in the ROM (flexion-extension) of wrist. In our study we inferred that lack of exercise is highly associated with the RJS. Strict inclusion criteria are the strength of this study. The drawback of this study we never studied the ulnar/radial deviation, since the results were obtained from surgically managed patient, it cannot be applied to all the DRF patient. Postoperative rehabilitation exercise is important for orthopedic surgery. A home exercise was considered to be as effective as formal physical therapy [33], but controversy still exists in other problems, for example, the timing of postoperative immobilization. A prospective randomized study compared early wrist exercise (i.e., within 2 weeks of surgery) with late wrist exercise (i.e., 6 weeks) in DRFs patients treated with volar plate fixation, and concluded that no significant differences were identified with respect to the average flexion-extension arc of the injured wrist at 3 or 6 months follow-up [34]. In our study, the lack of exercise within 3 months is common in these patients with improper rehabilitation exercise. We inferred that early or late exercise may not significantly affect the RJS, but the lack of exercise dose. Doctors' advice and patients' compliance during follow-up are essential for RJS prevention.

## CONCLUSION

Nearly half of the patients with distal radius fractures presented with post-operative radiocarpal joint stiffness following open reduction and internal fixation with a volar locking plate. An increase in age, peri-operative swelling, type of internal fixation, volar tilt, improper rehabilitation exercises were associated with the incidence of radiocarpal joint stiffness. However, volar tilt seems to be more dangerous than the restoration of radial inclination and radial

shortening for wrist dorsiflexion movement. Proper precautions and necessary measures to be taken pre - operatively and post-operatively for these patients.

**Conflict of Interest:** Not available

**Financial Support:** Not available

## REFERENCES

1. Wu, J. C., Strickland, C. D., & Chambers, J. S. (2019). Wrist fractures and osteoporosis. *Orthopedic Clinics*, 50(2), 211-221.
2. Zhang, X. J., Zhu, Y. B., Liu, S., Chen, W., Liu, B., Zhang, F., & Zhang, Y. Z. (2019). Incidence of low-energy upper extremity fractures and the risk factors in Chinese people 50 years or older. *Orthopaedic Surgery*, 11(2), 304-310.
3. Curtis, E. M., van der Velde, R., Moon, R. J., van den Bergh, J. P., Geusens, P., de Vries, F., & Harvey, N. C. (2016). Epidemiology of fractures in the United Kingdom 1988–2012: variation with age, sex, geography, ethnicity and socioeconomic status. *Bone*, 87, 19-26.
4. Johnson, N. A., Jeffery, J., Stirling, E., Thompson, J., & Dias, J. J. (2019). Effects of deprivation, ethnicity, gender and age on distal radius fracture incidence and surgical intervention rate. *Bone*, 121, 1-8.
5. Walenkamp, M. M., Goslings, J. C., Beumer, A., Haverlag, R., Leenhouts, P. A., Verleisdonk, E. J., & Schep, N. W. (2014). Surgery versus conservative treatment in patients with type A distal radius fractures, a randomized controlled trial. *BMC musculoskeletal disorders*, 15, 1-7.
6. Franceschi, F., Franceschetti, E., Paciotti, M., Cancilleri, F., Maffulli, N., & Denaro, V. (2015). Volar locking plates versus K-wire/pin fixation for the treatment of distal radial fractures: a systematic review and quantitative synthesis. *British medical bulletin*, 115(1), 91-110.
7. Smeraglia, F., Del Buono, A., & Maffulli, N. (2016). Wrist arthroscopy in the management of articular distal radius fractures. *British medical bulletin*, 119(1), 157-165.
8. Stinton, S. B., Graham, P. L., Moloney, N. A., MacLachlan, L. R., Edgar, D. W., & Pappas, E. (2017). Longitudinal recovery following distal radial fractures managed with volar plate fixation. *The Bone & Joint Journal*, 99(12), 1665-1676.
9. Dardas, A. Z., Goldfarb, C. A., Boyer, M. I., Osei, D. A., Dy, C. J., & Calfee, R. P. (2018). A prospective observational assessment of unicortical distal screw placement during volar plate fixation of distal radius fractures. *The Journal of hand surgery*, 43(5), 448-454.
10. Kong, L., Yang, G., Yu, J., Zhou, Y., Li, S., Zheng, Q., & Zhang, B. (2020). Surgical treatment of intra-articular distal radius fractures with the assistance of three-dimensional printing technique. *Medicine*, 99(8), e19259.
11. Curtis, E. M., van der Velde, R., Moon, R. J., van den Bergh, J. P., Geusens, P., de Vries, F., & Harvey, N. C. (2016). Epidemiology of fractures in the United Kingdom 1988–2012: variation with age, sex, geography, ethnicity and socioeconomic status. *Bone*, 87, 19-26.
12. Johnson, N. A., Jeffery, J., Stirling, E., Thompson, J., & Dias, J. J. (2019). Effects of deprivation, ethnicity, gender and age on distal radius fracture incidence and surgical intervention rate. *Bone*, 121, 1-8.
13. Walenkamp, M. M., Goslings, J. C., Beumer, A., Haverlag, R., Leenhouts, P. A., Verleisdonk, E. J., & Schep, N. W. (2014). Surgery versus conservative treatment in patients with type A distal radius fractures, a randomized controlled trial. *BMC musculoskeletal disorders*, 15, 1-7.
14. Franceschi, F., Franceschetti, E., Paciotti, M., Cancilleri, F., Maffulli, N., & Denaro, V. (2015). Volar locking plates versus K-wire/pin fixation for the treatment of distal radial fractures: a systematic review and quantitative synthesis. *British medical bulletin*, 115(1), 91-110.
15. Smeraglia, F., Del Buono, A., & Maffulli, N. (2016). Wrist arthroscopy in the management of articular distal radius fractures. *British medical bulletin*, 119(1), 157-165.
16. Keuchel-Strobl, T., Quadlbauer, S., Jurkowitsch, J., Rosenauer, R., Hausner, T., Leixnering, M., & Pezzei, C. (2020). Salvage procedure after malunited distal radius fractures and management of pain and stiffness. *Archives of Orthopaedic and Trauma Surgery*, 140, 697-705.
17. Kleinman, W. B. (2010). Distal radius instability and stiffness: common complications of distal radius fractures. *Hand clinics*, 26(2), 245-264.
18. Sato, K., Murakami, K., Mimata, Y., & Doita, M. (2018). Incidence of tendon rupture following volar plate fixation of distal radius fractures: A survey of 2787 cases. *Journal of orthopaedics*, 15(1), 236-238.
19. Uemura, T., Okano, T., Onode, E., Yokoi, T., Shintani, K., Okada, M., & Nakamura, H. (2018). Flexor pollicis longus tendon rupture by sandwiched underlying volar locking plate and distal radius. *Journal of Medical Ultrasonics*, 45, 647-651.
20. Gamba, C., Fernandez, F. A. M., Llavall, M. C., Diez, X. L., & Perez, F. S. (2017). Which immobilization is better for distal radius fracture? A prospective randomized trial. *International Orthopaedics*, 41, 1723-1727.

21. Kong, L., Lu, J., Zhou, Y., Tian, D., & Zhang, B. (2020). Incidence and risk factors for Redis placement after closed reduction and instant rigid cast immobilization for paediatric distal radius fractures: a case control study. *Journal of Orthopaedic Surgery and Research*, 15, 1-6.
22. Fok, M. W. M., Fang, C. X., Lau, T. W., Fung, Y. K. E., Fung, B. K. K., & Leung, F. K. L. (2018). The status of triangular fibrocartilage complex after the union of distal radius fractures with internal plate fixation. *International Orthopaedics*, 42, 1917-1922.
23. Zhang, P., Jia, B., Chen, X. K., Wang, Y., Huang, W., & Wang, T. B. (2018). Effects of surgical and nonoperative treatment on wrist function of patients with distal radius fracture. *Chinese Journal of Traumatology*, 21(01), 30-33.
24. Kim, J. K., Kim, D. J., & Yun, Y. (2016). Natural history and factors associated with ulnar-sided wrist pain in distal radial fractures treated by plate fixation. *Journal of Hand Surgery (European Volume)*, 41(7), 727-731.
25. Karnezis, I. A., Panagiotopoulos, E., Tyllianakis, M., Megas, P., & Lambiris, E. (2005). Correlation between radiological parameters and patient-rated wrist dysfunction following fractures of the distal radius. *Injury*, 36(12), 1435-1439.
26. Kong, L., Kou, N., Wang, Y., Lu, J., Tian, D., & Zhang, B. (2019). The necessity of restoration of radiologic parameters by closed reduction in elderly patients with distal radius fractures. *Medical Science Monitor: International Medical Journal of Experimental and Clinical Research*, 25, 6598-6604.
27. Grewal, R., & MacDermid, J. C. (2007). The risk of adverse outcomes in extra-articular distal radius fractures is increased with malalignment in patients of all ages but mitigated in older patients. *The Journal of hand surgery*, 32(7), 962-970.
28. Altissimi, M., Antenucci, R., Fiacca, C., & Mancini, G. B. (1986). Long-term results of conservative treatment of fractures of the distal radius. *Clinical Orthopaedics and Related Research*, 206, 202-210.
29. Krischak, G. D., Krasteva, A., Schneider, F., Gulkin, D., Gebhard, F., & Kramer, M. (2009). Physiotherapy after volar plating of wrist fractures is effective using a home exercise program. *Archives of physical medicine and rehabilitation*, 90(4), 537-544.
30. Forward, D. P., Davis, T. R. C., & Sithole, J. S. (2008). Do young patients with malunited fractures of the distal radius inevitably develop symptomatic post-traumatic osteoarthritis? *The Journal of Bone & Joint Surgery British Volume*, 90(5), 629-637.
31. Kopylov, P., Johnell, O., Redlund-Johnell, I., & Bengner, U. (1993). Fractures of the distal end of the radius in young adults: a 30-year follow-up. *Journal of Hand Surgery*, 18(1), 45-49.
32. Krischak, G. D., Krasteva, A., Schneider, F., Gulkin, D., Gebhard, F., & Kramer, M. (2009). Physiotherapy after volar plating of wrist fractures is effective using a home exercise program. *Archives of physical medicine and rehabilitation*, 90(4), 537-544.
33. Krischak, G. D., Krasteva, A., Schneider, F., Gulkin, D., Gebhard, F., & Kramer, M. (2009). Physiotherapy after volar plating of wrist fractures is effective using a home exercise program. *Archives of physical medicine and rehabilitation*, 90(4), 537-544.
34. Lozano-Calderón, S. A., Souer, S., Mudgal, C., Jupiter, J. B., & Ring, D. (2008). Wrist mobilization following volar plate fixation of fractures of the distal part of the radius. *JBJS*, 90(6), 1297-1304.