

International Journal of Medical and Pharmaceutical Research

Online ISSN-2958-3683 | Print ISSN-2958-3675
Frequency: Bi-Monthly
Available online on: https://ijmpr.in/

Original Article

Comparative Assessment of MRI Shoulder 3D VIBE Sequence and 3D CT for Quantification of Glenoid Bone Loss and Hill-Sachs Lesion Size in Recurrent Anterior Glenohumeral Instability

Sarju Yashvantbhai Patel, Tapas Pravinbhai Manvar, Chirag Arvindkumar Nayak, Kavya Jaiswal, Vipul Virabhai Solanki

Department of Radiodiagnosis, Government Medical College and Sir Takhtsinhji General Hospital, Bhavnagar, Gujarat, 364001 India.

OPEN ACCESS

Corresponding Author:

Tapas Pravinbhai Manvar
E-mail: tapas2106@gmail.com.

Received: 01-05-2026
Accepted: 29-05-2026
Available online: 30-06-2026

Copyright © *International Journal of Medical and Pharmaceutical Research*

ABSTRACT

Objective: To compare three-dimensional (3D) volumetric interpolated breath-hold examination (VIBE) magnetic resonance imaging (MRI) with 3D computed tomography (CT) for quantifying glenoid bone loss and Hill-Sachs lesion size in recurrent anterior glenohumeral instability.

Methods: In this hospital-based cross-sectional observational study, 30 adults (>18 years) with two or more documented anterior glenohumeral dislocations underwent both 3D CT and 3D VIBE MRI of the shoulder. Glenoid height, glenoid width, glenoid bone loss (mm and %) and Hill-Sachs lesion size (mm) were measured independently on both modalities using the best-fit circle method. Agreement was assessed by Bland-Altman analysis, and equivalence by two one-sided tests (TOST) with predefined margins (±1 mm for linear measurements; ±1.5% for percentage bone loss).

Results: CT and MRI values were closely concordant: glenoid height 37.53 ± 2.26 vs 37.63 ± 2.36 mm; glenoid width 24.55 ± 1.40 vs 24.32 ± 1.99 mm; glenoid bone loss 2.61 ± 1.10 vs 2.58 ± 1.18 mm (10.77 ± 4.41% vs 10.67 ± 4.54%); and Hill-Sachs size 4.85 ± 1.33 vs 4.77 ± 1.27 mm. Mean absolute differences were ≤0.23 mm (≤0.10% for bone loss percentage). TOST confirmed equivalence for every parameter (all $p < 0.0001$). Bland-Altman plots showed negligible bias, narrow 95% limits of agreement and no proportional bias.

Conclusions: 3D VIBE MRI produced glenoid bone loss and Hill-Sachs measurements statistically and clinically equivalent to 3D CT. It may be a reliable, radiation-free alternative to CT for preoperative bone-loss quantification in selected patients, while also providing soft-tissue characterization.

Keywords: Anterior shoulder instability; glenoid bone loss; MRI 3D sequence; 3D CT; Hill-Sachs lesion; glenohumeral instability.

INTRODUCTION

Recurrent anterior glenohumeral instability is a common cause of pain and disability in young, active adults, particularly those engaged in contact sports or repetitive overhead activity (Burkhart & De Beer, 2000). Repeated dislocation produces a Bankart lesion—avulsion of the anteroinferior labrum and capsule—and progressive attritional bone loss of the anterior glenoid rim, together with an impaction (Hill-Sachs) defect of the posterolateral humeral head (Itoi et al., 2003). Patients with substantial glenoid bone loss and an inverted-pear glenoid morphology carry a markedly higher risk of recurrence after arthroscopic Bankart repair, and biomechanical data indicate that as little as 21–25% glenoid width loss predisposes to instability (Itoi et al., 2003; Shin et al., 2017). Accurate preoperative quantification of bone loss is therefore central to surgical decision-making (arthroscopic Bankart repair vs. Latarjet/bone-block procedures).

Three-dimensional (3D) computed tomography (CT) remains the reference standard for glenoid bone loss quantification, permitting accurate en-face surface reconstruction and side-to-side comparison (Huijsmans et al., 2007; Sugaya et al., 2003), and correlates well with intraoperative findings (Bishop et al., 2013). However, it exposes young, often bilaterally affected patients to ionizing radiation and adds cost when magnetic resonance imaging (MRI) is already required for soft-tissue evaluation of the labrum, capsule, and rotator cuff (Kalra et al., 2004). Modern isotropic 3D MRI gradient-echo sequences (e.g., volumetric interpolated breath-hold examination, VIBE) can be reformatted in any plane and have shown early promise for quantifying osseous morphology with diagnostic performance approaching that of CT (Lee et al., 2013; Sgroi et al., 2022), while additionally characterizing labral, capsular, and cartilage injury and the glenoid track (Yamamoto et al., 2007). Whether the 3D VIBE sequence can reliably substitute for 3D CT in routine clinical assessment of glenoid and humeral bone loss, however, remains incompletely established, particularly in Indian clinical settings.

This study was undertaken to determine the agreement and statistical equivalence between MRI shoulder 3D VIBE and 3D CT shoulder for quantitative assessment of glenoid bone loss and Hill-Sachs lesion size in patients with recurrent anterior glenohumeral instability, with the aim of reducing radiation exposure and cost through single-modality (MRI-only) assessment where feasible.

MATERIALS AND METHODS

Study design and setting

This hospital-based cross-sectional observational study was conducted in the Department of Radiodiagnosis, Government Medical College and Sir Takhtsinhji General Hospital, Bhavnagar, from June 2024 to November 2025, after institutional ethics committee approval (Approval No. 1426/2024; dated 18/04/2024) and written informed consent from all participants.

Inclusion and exclusion criteria

Consecutive adults (>18 years) with two or more documented episodes of anterior glenohumeral dislocation, referred for shoulder MRI, were screened for eligibility. Exclusion criteria were prior surgery for shoulder instability and non-diagnostic or incomplete CT or MRI examinations. A feasibility sample of 30 participants was enrolled using consecutive convenience sampling, consistent with prior modality-comparison studies.

Imaging modalities and protocols

MRI: All examinations were performed on Siemens Magnetom Vida 3 Tesla scanners with a dedicated shoulder surface coil. Sequences included proton-density fat-suppressed planes and an isotropic 3D gradient-echo sequence (VIBE). Source data were reconstructed in the sagittal, coronal, and axial planes at 3-mm slice thickness.

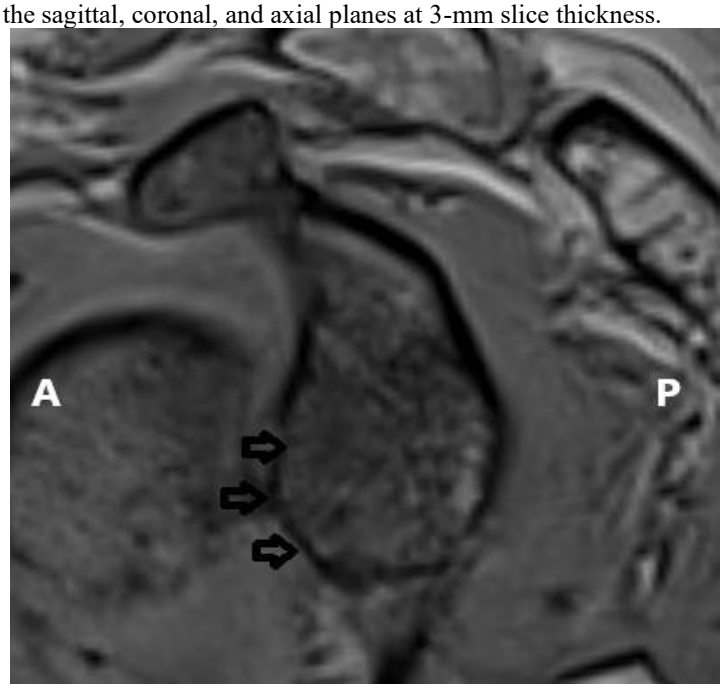

Figure 1. T1-weighted MR 3D sequence with en-face view image showing a normal pear-shaped glenoid with a curved anterior rim. 3D T1-weighted fast field-echo oblique MR image in an en-face view of the glenoid shows a normal pear-shaped glenoid with a smooth, curved anterior rim.



Figure 2. T1-weighted MR 3D sequence with en-face view image showing severe anterior glenoid bone loss. 3D T1-weighted fast spin echo MR image in an en-face view of the glenoid showing anterior glenoid bone loss (anterior straight line).

CT: Both-shoulder CT was acquired on GE Revolution 128-slice CT scanners. Multiplanar reformations (axial, coronal, sagittal) and 3D surface renderings were generated.

Measurement workflow and blinding

All DICOM datasets were anonymized and assigned study codes. Radiologists independently performed measurements on separate workstations, blinded to results and to the clinical data. For each modality and reader, glenoid defect size (mm and %), Hill-Sachs length (mm), width and depth, contralateral glenoid width where applicable, and a qualitative image-quality score were recorded, using the best-fit circle method on en-face reformats. Discrepancies were not adjudicated; per-modality means across readers were used for analysis.

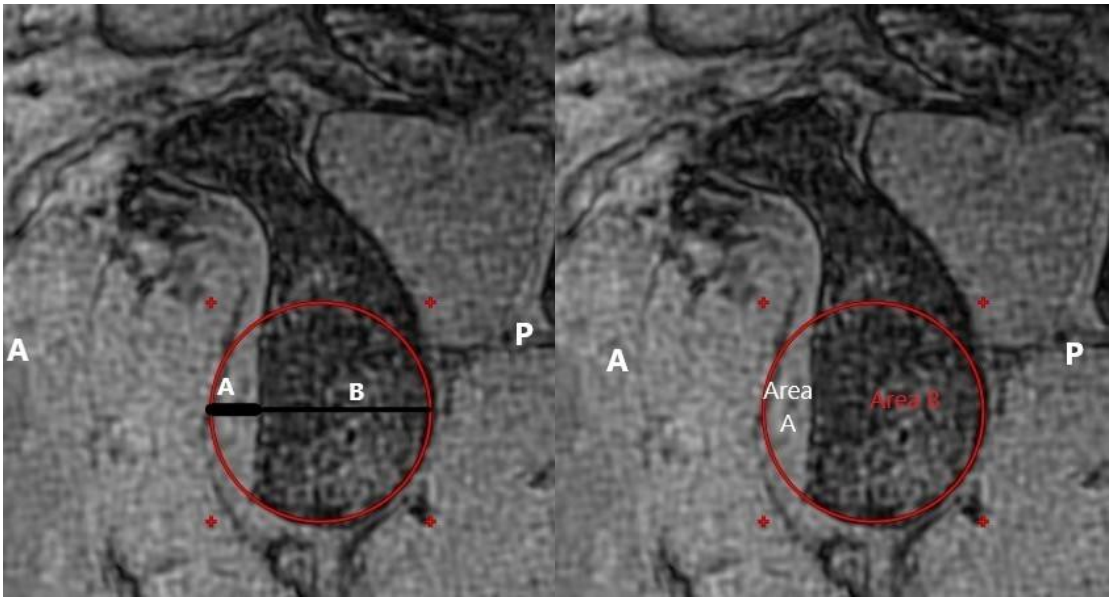

Figures 3 and 4. Glenoid bone loss assessment with dual methods on MRI 3D sequence (oblique imaging). Measurement of glenoid bone loss can be done using two approaches on the same high-resolution 3D T1-weighted fast field-echo oblique image obtained in an en-face view of the glenoid. (a) In the first method, the maximum transverse width of the remaining bony glenoid (B, thin line) is compared with the diameter of the best-fit circle representing the intact glenoid (A + B). Bone loss is calculated as the percentage reduction in width: A ÷ (A + B) × 100. (b) In the second method, the area of the bony defect (Area A, thick line) is measured within the best-fit circle. Bone loss is then expressed as the percentage reduction in area: Area A ÷ (Area A + Area B) × 100.

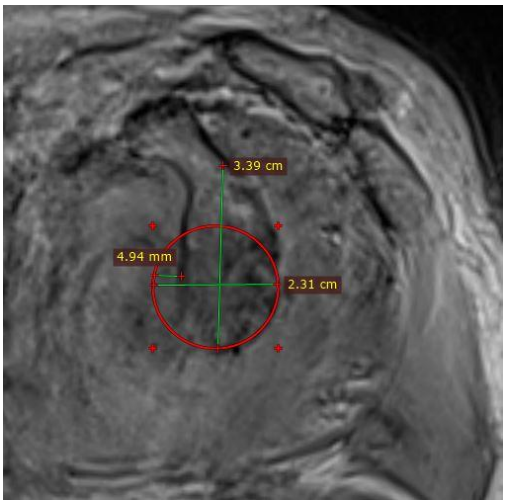

Figure 5. Glenoid bone loss measured on MRI using the 3D sequence in an older patient with a history of three right shoulder dislocations.



Figure 6. Glenoid bone loss measured on 3D CT.

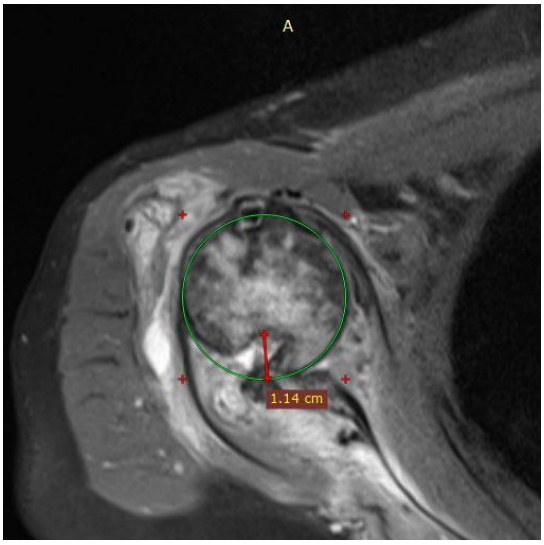

Figure 7. Hill-Sachs lesion.

Outcomes

The primary outcome was agreement and equivalence between CT and MRI 3D VIBE sequence for glenoid bone loss (mm and %). Secondary outcomes were agreement and equivalence for glenoid height, glenoid width, and Hill-Sachs lesion size.

Statistical analysis

Statistical analysis was performed using SPSS version 29.0 and R version 4.5.0. Continuous variables were summarized as mean ± standard deviation (SD); categorical variables as frequency and percentage. Agreement between CT and MRI 3D VIBE measurements was assessed using Bland-Altman analysis. Equivalence was assessed using a two one-sided tests (TOST) procedure with predefined clinically acceptable equivalence margins: ±1 mm for glenoid height, glenoid width, glenoid bone loss in millimeters, and Hill-Sachs lesion size; ±1.5% for glenoid bone loss percentage. A p-value <0.05 was considered statistically significant.

RESULTS

Thirty adult patients with recurrent anterior glenohumeral instability who underwent both CT and MRI of the shoulder met the eligibility criteria and had complete, analyzable imaging. The most prevalent age group was 20–29 years (n = 10, 33.3%), followed by 30–39 years (n = 7, 23.3%); the cohort was predominantly male (n = 27, 90%; female n = 3, 10%).

Table 1

Comparison of CT and MRI VIBE measurements for glenoid morphology, glenoid bone loss, and Hill-Sachs lesion size (n = 30)

Parameter	CT, mean ± SD	MRI VIBE, mean ± SD	Absolute mean difference	TOST p-value
Glenoid height (mm)	37.53 ± 2.26	37.63 ± 2.36	0.10 ± 1.31	<0.0001
Glenoid width (mm)	24.55 ± 1.40	24.32 ± 1.99	0.23 ± 1.47	<0.0001
Glenoid bone loss (mm)	2.61 ± 1.10	2.58 ± 1.18	0.03 ± 0.42	<0.0001
Glenoid bone loss (%)	10.77 ± 4.41	10.67 ± 4.54	0.10 ± 0.89	<0.0001
Hill-Sachs lesion size (mm)	4.85 ± 1.33	4.77 ± 1.27	0.08 ± 0.51	<0.0001

Note. CT = computed tomography; MRI = magnetic resonance imaging; VIBE = volumetric interpolated breath-hold examination; SD = standard deviation; TOST = two one-sided tests.

TOST analysis demonstrated statistically significant equivalence between CT and MRI VIBE for every parameter within the predefined margins (all $p < 0.0001$). Bland-Altman analysis showed mean bias close to zero for all parameters, with the majority of observations falling within the 95% limits of agreement and no evidence of proportional bias across the measurement range (e.g., glenoid height: mean bias ≈ 0, 95% limits of agreement approximately −2.6 to +2.8 mm).

DISCUSSION

This study found close numerical and statistical agreement between 3D CT and MRI 3D VIBE sequence for glenoid height, glenoid width, glenoid bone loss (mm and %), and Hill-Sachs lesion size (mm) in patients with recurrent anterior glenohumeral instability, with all parameters meeting predefined equivalence margins (TOST $p < 0.0001$) and negligible Bland-Altman bias. These findings are consistent with Stillwater et al. (2017), who found no significant difference between isotropic 3D-MR and 3D-CT osseous models of the shoulder, and with the more recent report by Cui et al. (2024), who demonstrated equivalence between a 3D MRI fast-field-echo sequence and 3D CT for quantifying bone loss and shoulder morphology. Lansdown et al. (2019) similarly showed that automated 3D MRI allows accurate evaluation of glenoid bone loss compared with 3D CT. In contrast, earlier work by Bishop et al. (2013) and Rerko et al. (2013) emphasized CT as the more reliable modality, reflecting the historical limitations of non-isotropic 2D MRI sequences that the newer isotropic 3D VIBE sequence appears to overcome.

Beyond quantitative equivalence, MRI VIBE offers the practical advantage of a single examination that concurrently evaluates labral, capsular, cartilage, and rotator cuff pathology—none of which is assessable on CT—while avoiding ionizing radiation in a predominantly young patient population who may require repeated or bilateral imaging over their lifetime.

Limitations

Sample size was limited to 30 patients from a single center; measurements were not validated against intraoperative or arthroscopic findings; and inter- and intra-observer agreement was not separately analyzed, as per-reader means were used for the primary comparison. Larger multicenter studies with arthroscopic correlation, formal observer-reliability analysis, and evaluation of glenoid track (on-track/off-track) classification are warranted.

CONCLUSION

The MRI shoulder 3D VIBE sequence provided glenoid and Hill-Sachs bone loss measurements statistically and clinically equivalent to 3D CT in patients with recurrent anterior glenohumeral instability. Given its additional capacity for soft-tissue

evaluation and avoidance of radiation, MRI 3D VIBE may be considered a reliable, radiation-free alternative to CT for preoperative bone-loss assessment in selected patients, particularly the young.

REFERENCES

1. Bishop, J. Y., Jones, G. L., Rerko, M. A., & Donaldson, C. (2013). 3D CT is the most reliable imaging modality when quantifying glenoid bone loss. *Clinical Orthopaedics and Related Research, 471*(4), 1245–1251. https://doi.org/10.1007/s11999-012-2607-x.
2. Burkhart, S. S., & De Beer, J. F. (2000). Traumatic glenohumeral bone defects and their relationship to failure of arthroscopic Bankart repairs. *Arthroscopy, 16*(7), 677–694. https://doi.org/10.1053/jars.2000.17715.
3. Cui, D. D., Long, Y., Yan, Y., Li, C., Yang, Y. T., Zhong, J. L., et al. (2024). Three-dimensional magnetic resonance imaging fast field echo resembling a computed tomography using restricted echo spacing sequence is equivalent to three-dimensional computed tomography in quantifying bone loss and measuring shoulder morphology in patients with shoulder dislocation. *Arthroscopy, 40*(6), 1777–1788. https://doi.org/10.1016/j.arthro.2023.12.016.
4. Huijsmans, P. E., Haen, P. S., Kidd, M., Dhert, W. J., van der Hulst, V. P., & Willems, W. J. (2007). Quantification of a glenoid defect with three-dimensional computed tomography and magnetic resonance imaging: A cadaveric study. *Journal of Shoulder and Elbow Surgery, 16*(6), 803–809. https://doi.org/10.1016/j.jse.2007.02.115.
5. Itoi, E., Lee, S. B., Amrami, K. K., Wenger, D. E., & An, K. N. (2003). Quantitative assessment of classic Bankart lesions by 3D reconstruction. *American Journal of Sports Medicine, 31*(1), 112–118. https://doi.org/10.1177/0363546503030310010301.
6. Kalra, M. K., Maher, M. M., Toth, T. L., Hamberg, L. M., Blake, M. A., & Shepard, J. A. (2004). Strategies for CT radiation dose optimization. *Radiology, 230*(3), 619–628. https://doi.org/10.1148/radiol.2303021726.
7. Lansdown, D. A., Cvetanovich, G. L., Verma, N. N., Cole, B. J., Bach, B. R., Nicholson, G., Romeo, A., Dawe, R., & Yanke, A. B. (2019). Automated 3-dimensional magnetic resonance imaging allows for accurate evaluation of glenoid bone loss compared with 3-dimensional computed tomography. *Arthroscopy, 35*(3), 734–740. https://doi.org/10.1016/j.arthro.2018.10.119.
8. Lee, R. K., Griffith, J. F., Tong, M., & Yung, P. S. (2013). Glenoid bone loss: Assessment with MR imaging using a 3D isotropic sequence. *Radiology, 267*(2), 496–502. https://doi.org/10.1148/radiol.12121681.
9. Rerko, M. A., Pan, X., Donaldson, C., Jones, G. L., & Bishop, J. Y. (2013). Comparison of various imaging techniques to quantify glenoid bone loss in shoulder instability. *Journal of Shoulder and Elbow Surgery, 22*(4), 528–534. https://doi.org/10.1016/j.jse.2012.05.034.
10. Sgroi, M., Huzurudin, H., Ludwig, M., Zippelius, T., Reichel, H., & Kappe, T. (2022). MRI allows accurate measurement of glenoid bone loss. *Clinical Orthopaedics and Related Research, 480*(9), 1731. https://doi.org/10.1097/CORR.0000000000002215.
11. Shin, S. J., Kim, R. G., Jeon, Y. S., & Kwon, T. H. (2017). Critical value of anterior glenoid bone loss that leads to recurrent instability after arthroscopic Bankart repair. *American Journal of Sports Medicine, 45*(9), 1975–1981. https://doi.org/10.1177/0363546517697963.
12. Stillwater, L., Koenig, J., Maycher, B., & Davidson, M. (2017). 3D-MR vs 3D-CT of the shoulder in patients with glenohumeral instability. *Skeletal Radiology, 46*(3), 325–331. https://doi.org/10.1007/s00256-016-2559-4.
13. Sugaya, H., Moriishi, J., Dohi, M., Kon, Y., & Tsuchiya, A. (2003). Glenoid rim morphology in recurrent anterior glenohumeral instability. *Journal of Bone and Joint Surgery, American Volume, 85*(5), 878–884. https://doi.org/10.2106/00004623-200305000-00016.
14. Yamamoto, N., Itoi, E., Abe, H., Minagawa, H., Seki, N., & Shimada, Y. (2007). Contact between the glenoid and the humeral head in abduction, external rotation, and horizontal extension: A new concept of glenoid track. *Journal of Shoulder and Elbow Surgery, 16*(5), 649–656. https://doi.org/10.1016/j.jse.2006.12.012.