International Journal of Medical and Pharmaceutical Research

Online ISSN-2958-3683 | Print ISSN-2958-3675
Frequency: Bi-Monthly
Available online on: https://ijmpr.in/

Original Article

Histopathological Study of Uterine Lesions in Hysterectomy Specimens- A Prospective Observational Study

Dr Srinidhi Kadagad[1], Dr Dipti Kolhar[2], Dr Shravani Gowrishankar[3]

[1,3]Assistant professor, Department of Pathology, Subbaiah Institute of Medical Sciences, Shimoga, Karnataka.
[2]Associate Professor, Department of Pathology, B.V.V. Sangha's S. Nijalingappa Medical College & Hanagal Shree Kumareshwar Hospital & Research Centre, Navanagar, Bagalkote, Karnataka.

OPEN ACCESS

Corresponding Author:

Dr Srinidhi Kadagad
Assistant professor, Department of Pathology, Subbaiah Institute of Medical Sciences, Shimoga, Karnataka.

Received: 05-06-2026
Accepted: 22-06-2026
Available online: 07-07-2026

Copyright © *International Journal of Medical and Pharmaceutical Research*

ABSTRACT

Background: Hysterectomy is one of the most frequently performed gynecological surgeries and remains the definitive treatment for a wide range of uterine pathologies. Histopathological examination of hysterectomy specimens provides valuable information regarding the spectrum of uterine lesions and their clinicopathological correlation.
Objectives: To evaluate the histopathological spectrum of uterine lesions in hysterectomy specimens and correlate the findings with age, parity, and clinical presentation.
Methods: This prospective observational study was conducted in the Department of Pathology, Shimoga Institute of Medical Sciences, over a period of 18 months. A total of 300 hysterectomy specimens with uterine lesions were included. Clinical details and histopathological findings were analyzed using descriptive statistics.
Results: The majority of patients belonged to the 41–50 years age group (46.33%), with a mean age of 44.6 years. Menorrhagia was the most common presenting complaint (41.33%), and uterine fibroid was the leading clinical indication for hysterectomy (54.67%). Leiomyoma was the most common histopathological lesion (69.00%), followed by adenomyosis (30.34%) and endometrial hyperplasia (9.00%). Endometrial carcinoma was identified in 2.67% of cases.
Conclusion: Leiomyoma was the predominant uterine lesion in hysterectomy specimens. Histopathological examination remains essential for confirming clinical diagnoses, identifying coexisting lesions, and ensuring appropriate patient management.

Keywords: *Adenomyosis; Endometrial Hyperplasia; Histopathology; Hysterectomy; Leiomyoma.*

INTRODUCTION

The female genital tract is a hormonally responsive system that undergoes a wide range of physiological and pathological changes throughout a woman's life, making it an important area of interest in gynecological practice.[1] It is broadly divided into the upper genital tract, comprising the uterus, cervix, fallopian tubes, and ovaries, and the lower genital tract.[2] Among these, the uterus is a major reproductive organ that exhibits significant structural and functional changes under hormonal influence. The corpus uteri consist of the endometrium and myometrium, with the endometrium undergoing cyclical hormonal changes and periodic shedding during menstruation.[3]

Various pathological lesions affecting the uterus contribute substantially to morbidity and mortality among women across different age groups. Common clinical manifestations of gynaecological disorders include abnormal uterine bleeding, infertility, per vaginal discharge, abdominal pain, pelvic masses, irregular menstrual cycles, and postmenopausal bleeding.[1] Despite the availability of several medical and conservative surgical treatment modalities, hysterectomy continues to remain one of the most commonly performed gynecological surgeries worldwide.[4]

Historically, the first subtotal hysterectomy was performed by Charles Clay in Manchester, England, in 1843, while the first total abdominal hysterectomy was carried out in 1929. Hysterectomy may be classified as total, subtotal, or supracervical, and may be performed with or without unilateral or bilateral salpingo-oophorectomy. The procedure can be undertaken through abdominal, vaginal, or laparoscopic approaches.[4]

Hysterectomy is indicated for a variety of benign and malignant conditions including leiomyoma, adenomyosis, endometriosis, endometrial hyperplasia, pelvic inflammatory disease, cervical dysplasia, uterine prolapse, gestational trophoblastic disease, and malignancies of the female reproductive tract.[5] Symptomatic pelvic organ prolapse remains one of the leading indications for vaginal hysterectomy.[6] Histopathological examination of hysterectomy specimens plays a crucial role in establishing definitive diagnosis and guiding further management. In certain situations, hysterectomy may also be performed even in the absence of significant gross or microscopic uterine pathology, particularly in conditions such as ovarian, fallopian tube, or vaginal malignancies, chronic pelvic inflammatory disease, endometriosis, dysfunctional uterine bleeding, pelvic pain, pelvic organ prolapse, and pelvic tuberculosis.[7]

Evaluation of hysterectomy specimens provides valuable insight into the spectrum and frequency of uterine lesions and helps correlate pathological findings with clinical presentation. Understanding the distribution of these lesions across different age groups and parity status is essential for improving diagnostic accuracy and therapeutic management. Hence, the present study was undertaken to evaluate the histopathological spectrum of uterine lesions in hysterectomy specimens, determine their incidence and distribution, and analyse their pattern of occurrence in relation to age, parity, and clinical presentation.

METHODOLOGY

Study Design and Setting

This was a hospital-based prospective observational study conducted in the Department of Pathology at Shimoga Institute of Medical Sciences over a period of 18 months. The study was undertaken to evaluate the histopathological spectrum of uterine lesions in hysterectomy specimens and correlate them with clinical parameters such as age, parity, and presenting complaints.

Study Sample

A total of 300 hysterectomy specimens received in the Department of Pathology during the study period were included in the study.

Inclusion Criteria

- Hysterectomy specimens showing uterine lesions.

Exclusion Criteria

- Specimens with incomplete or inadequate clinical details.
- Specimens showing isolated cervical, tubal, or ovarian pathology without significant uterine lesions.
- Autolyzed or poorly preserved specimens unsuitable for histopathological evaluation.

Ethical Considerations

Ethical clearance for the study was obtained from the Institutional Ethics Committee of Shimoga Institute of Medical Sciences prior to commencement of the study.

Study Procedure

Relevant clinical details including age, parity, presenting symptoms, and provisional clinical diagnosis were obtained from patient case records and requisition forms accompanying the specimens. All hysterectomy specimens received in the Department of Pathology were fixed immediately in 10% buffered formalin in a specimen-to-fixative ratio of 1:10 to ensure adequate preservation of tissue morphology.

Following fixation for a minimum period of 24 hours, detailed gross examination of the specimens was carried out. Gross features such as uterine size, endometrial thickness, myometrial appearance, presence of nodules, masses, haemorrhage, necrosis, and any other abnormal findings were carefully documented. Representative sections were taken systematically from the endometrium, myometrium, serosa, fundus, body, and lower uterine segment. Additional sections were obtained from any grossly identifiable lesion, including a minimum of three representative sections from each lesion wherever applicable.

The tissue specimens were processed by routine paraffin embedding technique. Sections of 3–5 µm thickness were cut using a rotary microtome and stained routinely with Hematoxylin and Eosin (H&E) stain for histopathological examination. Special stains such as Periodic Acid–Schiff (PAS) and other ancillary stains were employed whenever necessary to aid in diagnosis.

Data Analysis

The collected data were entered into Microsoft Excel and analysed using descriptive statistical methods. The results were expressed as frequencies, percentages, mean, and standard deviation wherever appropriate. Histopathological findings were analysed with respect to age distribution, parity, and clinical presentation.

RESULTS

A total of 486 hysterectomy specimens were received in the Department of Pathology during the 18-month study period, of which 300 histopathologically confirmed uterine lesion cases fulfilling the inclusion criteria were included in the study. The age of the patients ranged from 20 to 72 years, with a mean age of 44.6 years. The highest number of hysterectomies was observed in the 41–50 years age group (46.33%), followed by the 31–40 years age group (34.67%). Total abdominal hysterectomy with bilateral salpingo-oophorectomy (TAH+BSO) was the most commonly performed surgical procedure (77.33%). Uterine fibroid was the leading clinical indication for hysterectomy (54.67%), while menorrhagia was the most common presenting symptom (41.33%). The majority of patients were multiparous women (85.67%).

Table 1: Demographic and Clinical Profile of Patients Undergoing Hysterectomy (n=300)

Sl no	Variable	Frequency (n)	Percentage (%)
1	**Age Distribution**		
	11–20 years	1	0.33
	21–30 years	6	2.00
	31–40 years	104	34.67
	41–50 years	139	46.33
	51–60 years	38	12.67
	61–70 years	11	3.67
	>70 years	1	0.33
2	**Type of Hysterectomy**		
	TAH + BSO	232	77.33
	Vaginal hysterectomy	44	14.67
	TAH + USO	15	5.00
	Radical hysterectomy	8	2.67
	Subtotal hysterectomy	1	0.33
3	**Clinical Indications**		
	Uterine fibroid	164	54.67
	Adenomyosis	39	13.00
	DUB	22	7.33
	UV prolapse	20	6.67
	Clinical details not provided	18	6.00
	Polyp	10	3.33
	Endometrial carcinoma	9	3.00
	Endometrial hyperplasia	8	2.67
	PID	3	1.00
	Endometrial polyp	2	0.67
	Carcinoma cervix	2	0.67
	Chronic cervicitis	2	0.67
	Adherent placenta	1	0.33
4	**Parity**		
	Nulliparous	4	1.33
	Uniparous	39	13.00
	Multiparous	257	85.67

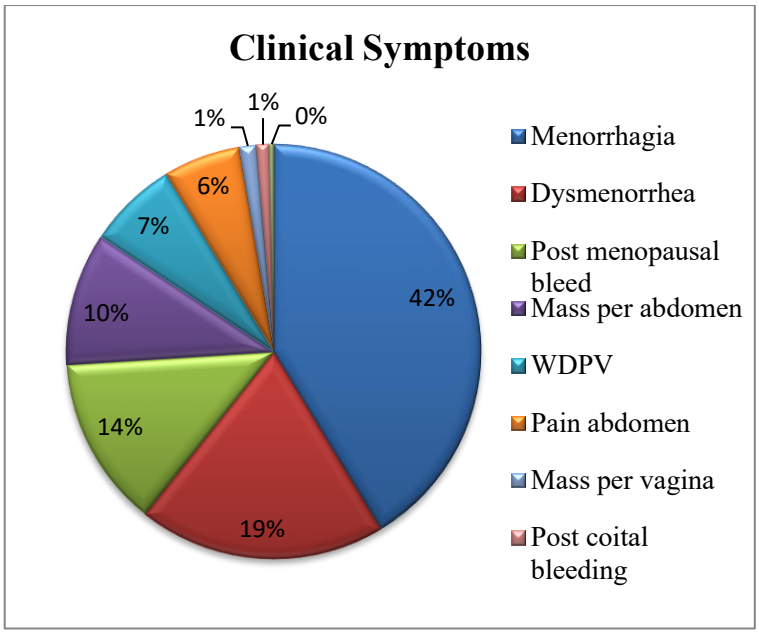

Figure 1: Clinical symptoms of patients undergoing Hysterectomy

Histopathological examination revealed a wide spectrum of endometrial and myometrial lesions. Proliferative endometrium (43.33%) and secretory endometrium (20.67%) were the predominant endometrial patterns observed. Among pathological lesions, atrophic endometrium was the most common endometrial abnormality (13.67%), followed by benign endometrial polyp (8.67%) and hyperplasia without atypia (7.67%). Leiomyoma was the predominant myometrial lesion, identified in 169 cases (56.33%), followed by adenomyosis in 53 cases (17.67%) and coexisting leiomyoma with adenomyosis in 38 cases (12.67%). Rare lesions encountered included endometrial stromal sarcoma in 1 case (0.33%), pyometra in 1 case (0.33%), adenomyoma in 2 cases (0.67%), metastatic carcinoma in 3 cases (1.00%), malignant mixed Müllerian tumour in 2 cases (0.67%), and adherent placenta in 1 case (0.33%).

Table 2: Histopathological Spectrum of Uterine Lesions in Hysterectomy Specimens (n=300)

Sl no	Histopathological Lesions	Number of Cases	Percentage
1	**Endometrial Lesions**		
	Proliferative endometrium	130	43.33
	Secretory endometrium	62	20.67
	Atrophic endometrium	41	13.67
	Hyperplasia without atypia	23	7.67
	Benign endometrial polyp	26	8.67
	Endometrial carcinoma	8	2.67
	Chronic endometritis	2	0.67
	Polyp with hyperplasia without atypia	4	1.33
	Polyp with chronic endometritis	1	0.33
	Endometrial stromal sarcoma	1	0.33
	Pyometra	1	0.33
	Adherent placenta	1	0.33
2	**Myometrial Lesions**		
	Leiomyoma	169	56.33
	Adenomyosis	53	17.67
	Leiomyoma with adenomyosis	38	12.67
	Endometrial carcinoma with myometrial invasion	8	2.67
	Adenomyoma	2	0.67
	Metastatic carcinoma	3	1.00
	MMMT/MMCS	2	0.67
	Adherent placenta	1	0.33
	Unremarkable myometrium	24	8.00

Leiomyoma was the most common uterine lesion overall, diagnosed in 207 cases (69.00%), including 169 isolated leiomyomas and 38 cases associated with adenomyosis. The highest frequency was observed in the 41–50 years age group (49.28%). Menorrhagia was the most frequent presenting complaint (41.55%), followed by dysmenorrhea

(23.67%). Intramural leiomyoma was the predominant location (55.56%), and typical leiomyoma constituted 79.71% of cases. Secondary degenerative changes were observed in 42 cases (20.29%), among which hyaline degeneration was the commonest type (76.19%). Adenomyosis was identified in 91 cases (30.34%), with most patients presenting in the 41–50 years age group (53.85%) and commonly complaining of menorrhagia (45.05%) and dysmenorrhea (27.47%). Endometrial hyperplasia was diagnosed in 27 cases (9.00%), predominantly in multiparous women (81.48%), with the majority belonging to the 31–40 years age group (44.44%). Endometrial carcinoma was identified in 8 cases (2.67%), most commonly affecting women aged 51–60 years (37.50%), and all patients presented with postmenopausal bleeding. Histologically, endometrioid carcinoma NOS was the most common subtype (87.50%), with grade 2 tumour being the predominant histological grade (50.00%).

Table 3: Clinicopathological Characteristics of Major Uterine Lesions

Sl no	Variable	Number of Cases	Percentage
1	**Leiomyoma (n=207)**		
	Age group 41–50 years	102	49.28
	Menorrhagia	86	41.55
	Dysmenorrhea	49	23.67
	Intramural location	115	55.56
	Typical leiomyoma	165	79.71
	Secondary degenerative changes	42	20.29
	Hyaline degeneration	32	76.19
	Cystic degeneration	4	9.52
	Calcification	2	4.76
	Myxoid degeneration	2	4.76
	Infarct	1	2.38
	Red degeneration	1	2.38
2	**Adenomyosis (n=91)**		
	Age group 41–50 years	49	53.85
	Menorrhagia	41	45.05
	Dysmenorrhea	25	27.47
3	**Endometrial Hyperplasia (n=27)**		
	Age group 31–40 years	12	44.44
	Menorrhagia	12	44.44
	Postmenopausal bleeding	9	33.33
	Multiparous women	22	81.48
4	**Endometrial Carcinoma (n=8)**		
	Age group 51–60 years	3	37.50
	Postmenopausal bleeding	8	100.00
	Endometrioid carcinoma NOS	7	87.50
	Villoglandular variant	1	12.50
	>50% myometrial invasion	6	75.00
	Grade 2 carcinoma	4	50.00

FIGURE 1: ENDOMETRIAL CARCINOMA SHOWING DIFFUSE GROWTH FILLING ENDOMETRIAL CAVITY ALONG WITH INTRAMURAL FIBROID

FIGURE 2: LOW GRADE ENDOMETRIAL STROMAL SARCOMA SHOWING POORLY DEFINED YELLOW TO TAN MASS.

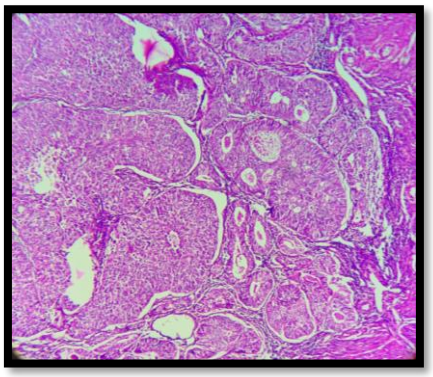

FIGURE 3: MODERATELY DIFFERENTIATED ENDOMETRIOID CARCINOMA (H&E) 10 X

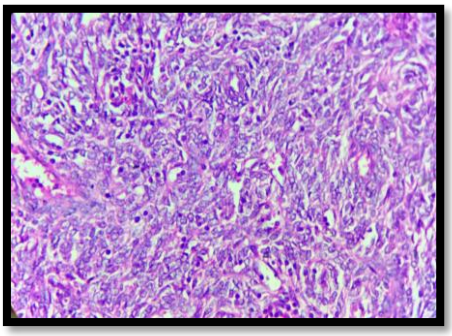

FIGURE 4: LOW GRADE ENDOMETRIAL STROMAL SARCOMA (H&E) 40X

DISCUSSION

Hysterectomy remains one of the most commonly performed gynecological surgeries worldwide and serves as a definitive treatment modality for a broad spectrum of benign and malignant uterine pathologies. The present study was undertaken to evaluate the histopathological spectrum of uterine lesions in hysterectomy specimens and to correlate these findings with age, parity, and clinical presentation.

In the present study, the age of patients undergoing hysterectomy ranged from 20–72 years, with the majority belonging to the 41–50 years age group (46.33%). Similar observations were reported by Gousia Rahim Rather[8] and Mohammad Sajjad[9], who also documented peak incidence in the fourth and fifth decades of life. The mean age in the present study was 44.6 years, which was comparable with studies conducted by Sujatha R[10] and Subrata P.[11] The predominance of hysterectomy in the perimenopausal age group may be attributed to the increased prevalence of symptomatic uterine lesions during this period.

Total abdominal hysterectomy with bilateral salpingo-oophorectomy was the most frequently performed procedure, accounting for 77.33% of cases, followed by vaginal hysterectomy (14.67%). Comparable findings were observed in studies by Baral R[12] and K Usha. The preference for abdominal hysterectomy in the present study likely reflects the high prevalence of leiomyoma and adenomyosis requiring definitive surgical management. Uterine fibroid was the most common clinical indication for hysterectomy (54.67%), followed by adenomyosis (13%). Similar findings have been

reported by Chryssikopoulos[14] and Roopali Jandial.[15] Menorrhagia was the predominant presenting complaint (41.33%), which correlated well with observations made by Sujatha R[10] and Simrat Jit Kaur.[16] The majority of patients in the present study were multiparous women, consistent with previous reports in the literature.

Histopathological evaluation demonstrated that proliferative endometrium was the most common endometrial pattern, while atrophic endometrium represented the most frequent pathological endometrial lesion (13.67%). Endometrial polyps and hyperplasia without atypia were also commonly encountered. These findings were comparable to studies by Roopali Jandial[15] and Jaya Maisnam.[17] In contrast, some authors including Gousia Rahim Rather[8] and K Usha[10] reported endometrial hyperplasia as the predominant endometrial pathology. Leiomyoma was the most common myometrial lesion identified in the present study, accounting for 56.33% of cases, while adenomyosis constituted 17.67%. Overall, leiomyoma was identified in 69% of hysterectomy specimens, including cases associated with adenomyosis. These observations were consistent with findings reported by Roopali Jandial[15] and other comparable studies.[16,17] The peak incidence of leiomyoma was observed in the 41–50 years age group, similar to the study by Gowri M.[18] Menorrhagia was the most frequent presenting symptom associated with leiomyoma, and most cases occurred in multiparous women.

Intramural leiomyoma was the predominant location observed in the present study. Secondary degenerative changes were noted in 20.29% of leiomyomas, with hyaline degeneration being the most common type (76.19%). Similar findings have been documented in studies by Simrat Jit Kaur, Gowri M, and Manpreet Kaur.[16,18,19] Adenomyosis was identified in 30.34% of cases, either as an isolated lesion or in association with leiomyoma. Most patients belonged to the 41–50 years age group and presented with menorrhagia and dysmenorrhea. The majority were multiparous women, which correlated with studies by IM Vora, Bird, and Paola Vercellini.[20-22]

Endometrial hyperplasia constituted 9% of cases, with the majority representing hyperplasia without atypia. Most cases occurred in women aged 31–40 years and commonly presented with menorrhagia. Similar findings were reported by Subrata P[11] and Divya Shekar Shetty.[23]
Endometrial carcinoma was diagnosed in 2.67% of hysterectomy specimens. Most patients belonged to the 51–60 years age group and presented with postmenopausal bleeding. Histologically, endometrioid carcinoma NOS was the predominant subtype. Grade 2 tumors and >50% myometrial invasion were more frequently observed. These findings were comparable with studies by Sumangala G and P J D Milton.[24,25] Rare lesions encountered in the present study included low-grade endometrial stromal sarcoma, pyometra, adenomyoma, chronic endometritis, metastatic carcinoma, and adherent placenta. Three cases of metastatic carcinoma involving the uterus were identified, all secondary to ovarian carcinoma. The identification of such uncommon lesions highlights the importance of meticulous histopathological examination of all hysterectomy specimens.

CONCLUSION

The present study demonstrates that leiomyoma was the most common uterine lesion encountered in hysterectomy specimens, followed by adenomyosis and endometrial hyperplasia. Menorrhagia was the predominant presenting complaint, and most patients belonged to the perimenopausal age group. Histopathological examination not only confirmed the clinically suspected diagnosis but also identified several incidental and coexisting lesions that were not recognized clinically or on gross examination. Therefore, detailed histopathological evaluation of every hysterectomy specimen is essential for accurate diagnosis, appropriate postoperative management, and optimal patient follow-up.

REFERRENCES

1. Konar H, editor. *Dutta DC's Textbook of Gynecology*. 9th ed. New Delhi: Jaypee Brothers Medical Publishers; 2023.
2. Berek JS, editor. *Berek & Novak's Gynecology*. 16th ed. Philadelphia: Wolters Kluwer; 2019.
3. Kumar V, Abbas AK, Aster JC. *Robbins and Cotran Pathologic Basis of Disease*. 10th ed. Philadelphia: Elsevier; 2020.
4. Lobo RA, Gershenson DM, Lentz GM, Valea FA, editors. *Comprehensive Gynecology*. 8th ed. Philadelphia: Elsevier; 2022.
5. Arulkumaran S, editor. *Jeffcoate's Principles of Gynaecology*. 9th ed. New Delhi: Jaypee Brothers Medical Publishers; 2018.
6. Hoffman BL, Schorge JO, Bradshaw KD, Halvorson LM, Schaffer JI, Corton MM. *Te Linde's Operative Gynecology*. 12th ed. Philadelphia: Wolters Kluwer; 2020.
7. Kurman RJ, Ellenson LH, Ronnett BM, editors. *Blaustein's Pathology of the Female Genital Tract*. 6th ed. New York: Springer; 2011.
8. Rather GR, Gupta Y, Bardhwaj S. Patterns of lesions in hysterectomy specimens: A prospective study. JK Sci. 2013;15(2):63-68.
9. Sajjad M, Akram M, Khan ZA, Ghafoor A. Pattern of histopathological lesions in uterine corpus of hysterectomy specimens. Gomal J Med Sci. 2015;13(1):58-61.

10. Sujatha R, Jaishree T, Manjunatha YA. Histomorphological analysis of uterine and cervical lesions in hysterectomy specimens at a tertiary care hospital. J Diagn Pathol Oncol. 2019;4(1):72-77.
11. Subrata P, Srabani C, Anuradha S, Prakash PJ, et al. A retrospective clinico-pathological study of hysterectomy cases in a tertiary care hospital in India – a review of 950 cases. Bangladesh J Med Sci. 2018;17(1):88-92.
12. Baral R, Sherpa P, Gautam D. Histopathological analysis of hysterectomy specimens: one year study. J Pathol Nepal. 2017;7:1084-1086
13. Usha K, Maheswari J. Histopathological spectrum of lesions in hysterectomy specimens at a tertiary care hospital – one year study. IOSR J Dent Med Sci. 2017;16(10):34-38.
14. Chryssikopoulos A, Loghis C. Indications and results of total hysterectomy. Int Surg. 1986;71(3):188-194.
15. Jandial R, Choudhary M, Singh K. Histopathological analysis of hysterectomy specimens in a tertiary care centre: study of 160 cases. Int Surg J. 2019;6:2856-2859.
16. Kaur SJ, Gupta RK, Kaur M. Clinicopathological study of uterine lesions in hysterectomy specimens. Ann Int Med Dent Res. 2018;4(1):18-22.
17. Maisnam J, Kumar NBJ, Hasan Z. Spectrum of lesions in hysterectomy specimens – A one year retrospective study. J Evid Based Med Healthc. 2018;5(36):2656-2659.
18. Gowri M, Mala G, Murthy S, Nayak V. Clinicopathological study of uterine leiomyomas in hysterectomy specimens. J Evol Med Dent Sci. 2013;2(46):9002-9009.
19. Kaur M, Agarwal A, Das C, Kundal RK, Mall N, Jindal S. Clinicopathological study of 100 cases of hysterectomies in a tertiary care centre. Ann Int Med Dent Res. 2018;4(3):09-12.
20. Vora IM, Raizada RM, Rawal MY, Chadda JS. Adenomyosis. J Postgrad Med. 1981;27:7-11.
21. Bird CC, McElin TW, Estrella P. The elusive adenomyosis of the uterus revisited. Am J Obstet Gynecol. 1972;112(5):583-589.
22. Vercellini P, Parazzini F, Oldani S, Bramante T, Panazza S, Crosignani PG. Adenomyosis at hysterectomy: a study on frequency distribution and patient characteristics. Hum Reprod. 1995;10(5):1160-1162.
23. Shetty DS, Gosavi AV, Murarkar PS, Sulhyan KR. Endometrial hyperplasia: recent updates and clinicopathological correlation. Comp Clin Pathol. 2018;27:199-204.
24. Sumangala G, Premalatha TS, Kulkarni KA, Acharya G, Bidkar VC. A profile of endometrioid adenocarcinoma of uterus in a tertiary centre. Indian J Pathol Oncol. 2019;6(1):80-83.
25. Milton PJD, Metters JS. Endometrial carcinoma: An analysis of 355 cases treated at St. Thomas' Hospital. J Obstet Gynaecol Br Commonw. 1972;79:455-464.