



Case Series


Use of Antibiotic Cement Beads (STIMULAN) for Chronic Osteomyelitis Treatment and Peripheral New Bone Formation: A Case Series

Dr. Nivas S Gowda¹, Dr. Saragur Anand D², Dr. Chidananda B B³

¹Assistant Professor, Department of Orthopaedics, Kodagu institute of Medical Sciences Madikeri, Kodagu, Karnataka, India

²Senior Resident, Department of Orthopaedics, Kodagu institute of Medical Sciences Madikeri, Kodagu, Karnataka, India.

³Senior Resident, Department of Orthopaedics, Kodagu institute of Medical Sciences Madikeri, Kodagu, Karnataka, India

 OPEN ACCESS

Corresponding Author:

Dr. Chidananda B B

Senior Resident, Department of
Orthopaedics, Kodagu institute of
Medical Sciences Madikeri, Kodagu,
Karnataka, India

Received: 30-05-2026

Accepted: 15-06-2026

Available online: 04-07-2026

Copyright © International Journal of
Medical and Pharmaceutical Research

ABSTRACT

Introduction: Chronic osteomyelitis poses a significant challenge in orthopedic practice, often requiring comprehensive management strategies. Antibiotic-loaded cement beads, such as STIMULAN, have emerged as a potential treatment modality, providing local antibiotic delivery and aiding in bone regeneration. This case series investigates the efficacy of STIMULAN in treating chronic osteomyelitis and its impact on peripheral new bone formation.

Objectives:

Primary objectives encompass:

1. Assessing the effectiveness of antibiotic cement beads (STIMULAN) in eradicating chronic osteomyelitis.

2. Evaluating the role of STIMULAN in promoting peripheral new bone formation.

Methods and Materials: This case series retrospectively analyzes 15 patients (5 – distal tibia, 4 – distal femur, 2 – proximal tibia, 2 – humerus, 1 – pubic symphysis, 1 – radius) with chronic osteomyelitis treated using STIMULAN antibiotic cement beads for the dead space created following debridement and removal of necrosed tissue. Clinical signs, infection control, blood markers and postoperative functional outcomes were recorded. Radiographic assessments documented bone healing.

Observation: Findings indicate 93.3 % of patients achieved successful eradication of chronic osteomyelitis post-STIMULAN treatment with absence of clinical signs and normalisation of blood markers

. Peripheral new bone formation was evident in 80 % of cases, demonstrating progressive ossification around the affected sites. No major complications related to STIMULAN occurred during follow-up.

Conclusion: Antibiotic cement beads (STIMULAN) exhibit efficacy in eradicating chronic osteomyelitis and promoting peripheral new bone formation. This approach presents a promising adjunctive therapy, providing local antibiotic delivery while facilitating bone regeneration. STIMULAN holds potential as an effective treatment option in managing chronic osteomyelitis, warranting further investigation to solidify its role in clinical practice.

Keywords: efficacy and safety, pain on vas, quality of life (QOL), irritable bowel syndrome, treatment of IBS.

INTRODUCTION

Osteomyelitis is a bone and bone marrow infection, with Staphylococcus aureus being the causative pathogen in 30-60% of human cases, and staphylococci alone causing approximately 75% of cases. Treatment for acute, uncomplicated osteomyelitis typically involves antibiotics alone, administered for 4-6 weeks, with a success rate of around 80%. However, chronic osteomyelitis often requires surgical debridement in addition to antibiotics, as antibiotic therapy alone has a low success rate. Debridement surgery can be challenging, and treating the resulting dead space can be complex,

leading to prolonged healing times¹ Despite optimal medical and surgical treatment, there's still a 20% chance of treatment failure in complicated cases³

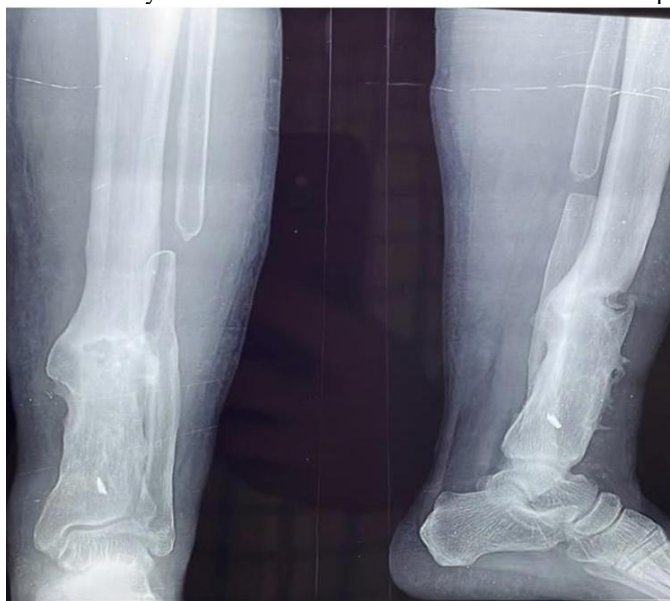The concept of a single-stage procedure for chronic osteomyelitis has been explored in specialist centers over the past 20 years, with various methods described to provide skeletal stability and eliminate dead space post-debridement. Currently, there's no consensus or guidelines on the best management approach for chronic osteomyelitis⁴

In this study, we used antibiotic-loaded absorbable calcium sulphate cement beads (STIMULAN) to manage the dead space effectively

CASE STUDY

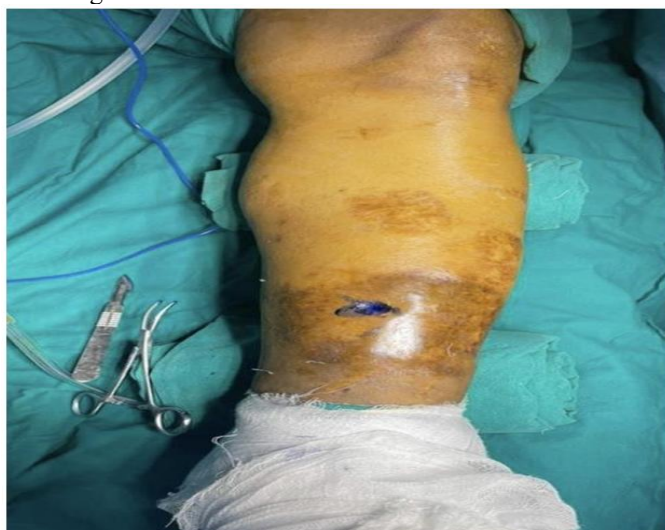Case 1: Distal Tibia Osteomyelitis. 26 years male with chronic osteomyelitis distal tibia pain and discharging sinus at anteromedial part of the leg since 6 months Clinical examination revealed discharging sinus with serous discharge, local rise of temperature with tenderness present at distal tibia.

X -ray revealed chronic osteomyelitis features like focal sclerotic lesion with sequestrum and cloaca.

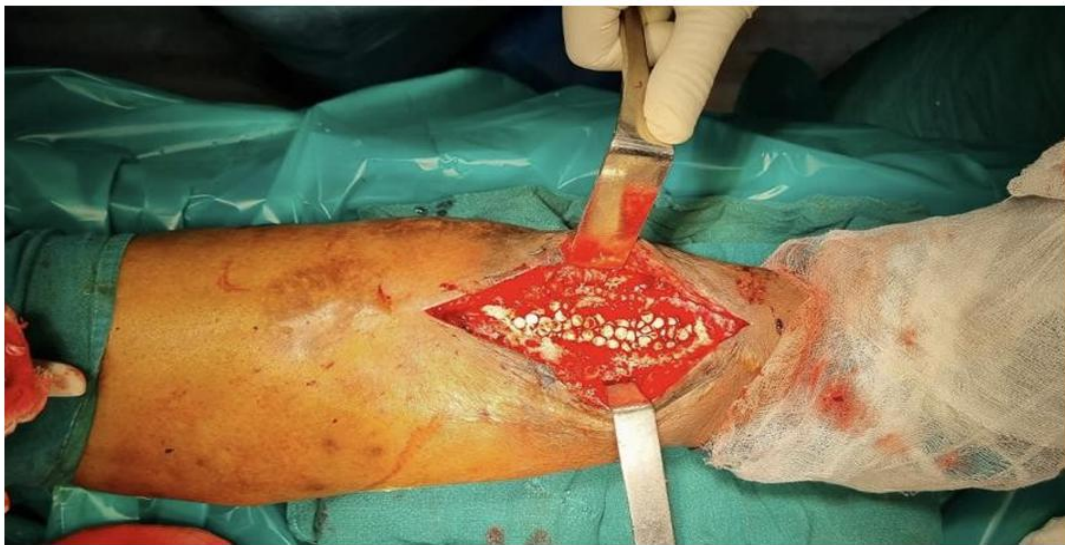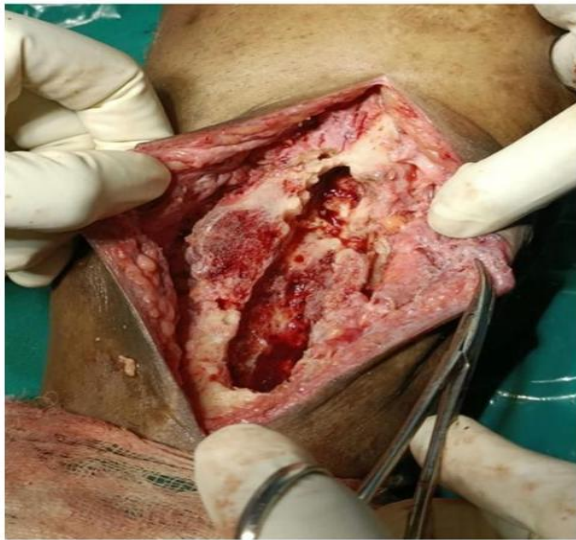


Blood investigations showed raised inflammatory markers ESR – 60 mm CRP - 123

Under all aseptic precautions Methylene blue is injected through the sinus and tract is extracted out, bone is entered through cloaca and a bone window is generated.

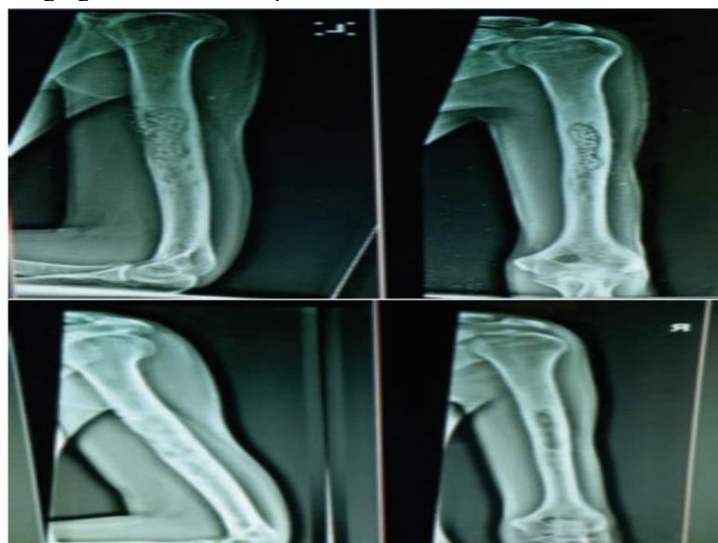

Thorough debridement was done and all necrotic debris is taken out. Bone defect generated is filled with vancomycin mixed calcium sulphate 3mm beads. Skin closed in layers.

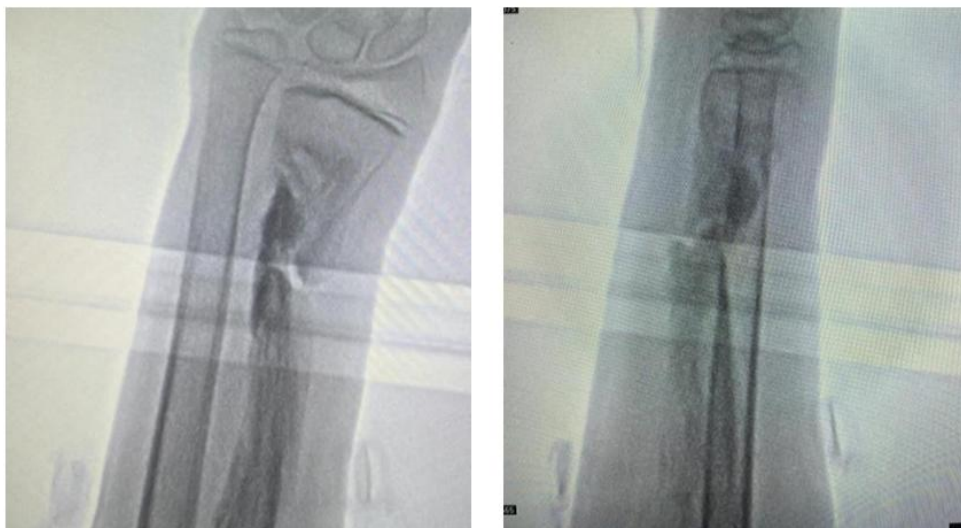

IV antibiotic was given for 2 weeks followed by oral antibiotics for another 2 weeks. Post operative period was uneventful. Follow up was done at 6 weeks, 3 months, 6 months.

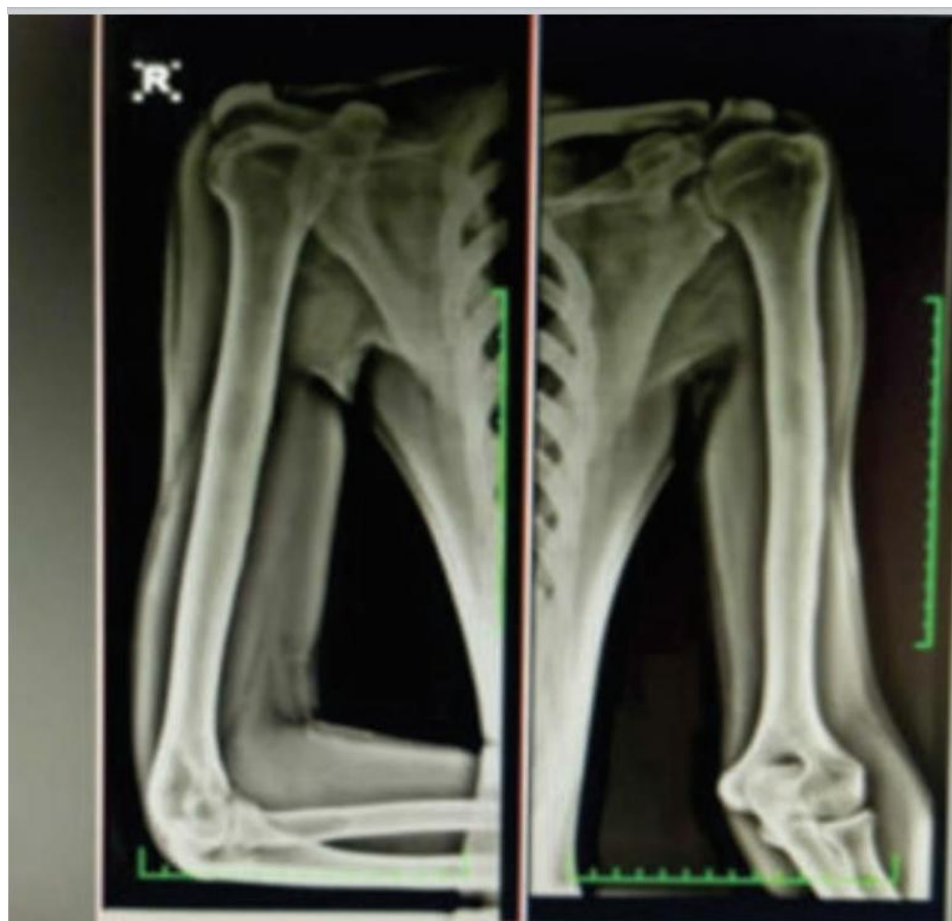Case 2 :Chronic osteomyelitis of midshaft humerus Presenting a case of 23 year old male with chronic osteomyelitis with complaints of pain and discharging sinus at anterior part of arm since 6 months.



Case 3 : Chronic osteomyelitis of Distal third shaft of radius 17 year old male with swelling and discharging sinus from the right forearm since 9 months



At 6 months complete bone healing was seen.



RESULTS

93.3 % of patients achieved successful eradication of chronic osteomyelitis post-STIMULAN treatment with absence of clinical signs and normalisation of blood markers . Peripheral new bone formation was evident in 80 % of cases, demonstrating progressive ossification around the affected sites. No major complications related to STIMULAN occurred during follow-up.

DISCUSSION

While systemic antibiotics can eradicate infections in some cases, many treatment strategies rely on local antibiotic delivery to achieve effective concentrations at the infection site. This is because systemic treatment often can't achieve

the required local minimum inhibitory concentration (MIC), minimal bactericidal concentration (MBC), or minimal biofilm eradication concentration (MBEC) due to biofilm development and poor vascularization.

Various biomaterials have been used or are being explored for local antibiotic delivery, classified into non-degradable and biodegradable categories. Calcium sulphate (CaSO₄) is an inorganic, biodegradable option with three forms: anhydrous, hemihydrated, and dihydrated. STIMULAN is a synthetic, pure hemihydrated form⁶

Calcium sulphate is preferred over PMMA for filling voids and delivering antibiotics, as it's absorbed and removed from the implantation site, stimulating new bone growth. It's biocompatible, osteoconductive, and osteointegrative, with a degradation profile matching bone formation (4-8 weeks)^{7,8}

Potential complications of calcium sulphate use include prolonged wound drainage (4.2%), transient hypercalcemia (5.4%), and heterotopic ossification (1.7%)⁹ However, in our cases, no complications were observed, and calcium sulphate globules were absorbed within 4-6 weeks, with complete bone healing in 5-6 months.

CONCLUSION

We conclude that antibiotic laden absorbable calcium sulphate cement beads are effective mode of treatment in management of dead space created after meticulous debridement and excision of necrosed bone and soft tissue in chronic osteomyelitis

REFERENCES

1. Am J Pathol 2020, 190: 1151e1163; <https://doi.org/10.1016/j.ajpath.2020.02.007>
 2. McNally M, Nagarajah K: (iv) Osteomyelitis. Orthop Traumatol 2010, 24:416e429
 3. Conterno LO, Turchi MD: Antibiotics for treating chronic osteomyelitis in adults. Cochrane Database Syst Rev 2013, 9: CD004439
 4. Pincher et al. Journal of Orthopaedic Surgery and Research (2019) 14:393 <https://doi.org/10.03:01PM1186/s13018-019-1388-203:01> PM.
 5. EFORT Open Rev 2021;6:297-304. DOI: 10.1302/2058-5241.6.200083
 6. Zachary Lum C, Gavin Pereira C. Local bio-absorbable antibiotic delivery in calcium-sulfate beads in hip and knee arthroplasty, Journal of Orthopaedics. 2018;15(2).
 7. Peltier LF. The use of plaster of Paris to fill large defects in bone. Am J Surg 1959;97:311–315.
 8. Kumar YC, Nalini KB, Menon J, Patro DK, Banerji BH. Calcium sulfate as bone graft substitute in the treatment of osseous bone defects, a prospective study. J Clin Diagn Res 2013;7:2926–2928
- Kallala R, Harris WE, Ibrahim M, Dipane M, McPherson E. Use of Stimulan absorbable calcium sulphate beads in revision lower limb arthroplasty: Safety profile and complication rates. Bone Joint Res. 2018 Nov 3;7(10):570-579. doi: 10.1302/2046-3758.710.BJR-2017-0319.R1. PMID: 30464837; PMCID: PMC6215242.