



Original Article

## Laparoscopic Appendectomy Using Hem-O-Lok Clips: A Hospital-Based Prospective Observational Study

Dr Lokendra Singh<sup>1</sup>, Prof (Dr) Abdul Rashid Ganai<sup>2</sup>, Dr G M Naikoo<sup>3</sup>, Dr Yaser Hussain Wani<sup>4</sup>, Dr Razaq Hussain<sup>5</sup>, Dr Mehak Iqbal<sup>6</sup>

<sup>1,5,6</sup>Postgraduate Scholars, Postgraduate Department of Minimal Access and General Surgery, Government medical colleges Srinagar

<sup>2</sup>Professor, Department of Minimal Access and General Surgery, Government medical colleges Srinagar

<sup>3</sup>Associate Professor, Department of Minimal Access and General Surgery, Government medical colleges Srinagar

<sup>4</sup>Assistant Professor, Department of General Surgery in Kashmir Medical College Srinagar

 OPEN ACCESS

### Corresponding Author:

**Dr. G. M Naikoo**

Associate Professor, Department of Minimal Access and General Surgery, Government medical colleges Srinagar

Received: 09-05-2026

Accepted: 20-06-2026

Available online: 02-07-2026

### ABSTRACT

**Background:** Because it causes less postoperative pain, shorter hospital stay and faster recovery, laparoscopic appendectomy is the preferred surgical treatment of acute and recurrent appendicitis. The most important step to prevent postoperative complications is the secure closure of the stump of the appendix. Hem-o-lok polymer clips are a feasible, cost-effective and technically convenient alternative for the closure of the appendiceal stump.

**Aims:** To assess the effectiveness and safety of Hem-o-lok clips in laparoscopic appendectomy for appendiceal stump closure.

**Materials and Methods:** This was a prospective observational study done in the Department of Minimal Access and General Surgery, Government Medical College Srinagar. The study was conducted for a period of 18 months from March 2024 to September 2025. We enrolled a total of 36 patients who underwent laparoscopic appendectomy and closure of appendiceal stump with Hem-o-lok clips. Demographic profile, operative time, length of hospital stay and postoperative complications were analyzed using statistical methods.

**Results and discussion:** Mean age of patients was  $30.14 \pm 13.47$  years with female predominance (72.2%). The most common presentation was recurrent appendicitis (58.3%). Mean operative time was  $53.5 \pm 21.5$  minutes. Most procedures were performed in 41–60 minutes. Postoperative recovery was good with few complications in most of the cases. There was no stump leak, intra-abdominal abscess, or mortality.

**Conclusion:** The use of hem-o-lok clips is a safe, reliable and technically feasible technique for appendiceal stump closure in laparoscopic appendectomy. They are related to acceptable operative time, low complication rates and favorable postoperative results.

Copyright © International Journal of Medical and Pharmaceutical Research

**Keywords:** Appendicitis, Laparoscopic appendectomy, Hem-o-lok clips, Appendiceal stump closure, Polymeric clips.

### INTRODUCTION

Acute appendicitis is one of the most common causes of acute abdomen worldwide requiring emergency surgical intervention. The disease is caused by obstruction of the appendiceal lumen by lymphoid hyperplasia, fecoliths, tumors or

parasites, which causes inflammation, ischemia, and bacterial overgrowth, which can ultimately lead to necrosis if left untreated [1]. Appendicitis is most common in young adults with peak incidence in the 2nd and 3rd decades of life [2].

For over a century the gold standard procedure has been the open appendectomy. However, since the first laparoscopic appendectomy by Semm in 1982 [3], minimally invasive surgery has revolutionized the management of appendicitis. Laparoscopic appendectomy has many advantages such as decreased postoperative pain, shorter hospital stay, faster recovery, better cosmetic outcome and lower wound infection rates [4].

One of the most important steps in laparoscopic appendectomy is the safe closure of the appendiceal stump. Inadequate stump closure can lead to severe postoperative complications such as fecal fistula, stump leak, intra-abdominal abscess and peritonitis [5]. Endoloops, intracorporeal sutures, staplers, metallic clips, and polymeric clips are some of the techniques that have been used for appendiceal stump closure [6].

Endoscopic staplers are reliable for closure but increase the cost of the procedure markedly [7]. Endoloops are less expensive but technically difficult and time-consuming (8). Hem-o-lok clips are nonabsorbable polymer clips with locking mechanisms that are designed to provide secure tissue ligation. The clips are radiolucent and inert, easy to apply, and associated with shorter operative time. [9]

There are many studies that demonstrate the safety and efficacy of Hem-o-lok clips in laparoscopic appendectomy. Clips offer adequate compression at the base of the appendix and decrease operative complexity with low complication rates [10–12]. These have gained popularity over the years due to ease of application and cost-effectiveness.

There is increasing evidence on the efficacy of Hem-o-lok clips in laparoscopic appendectomy, but there is limited prospective observational data from tertiary care hospitals in the Indian subcontinent. Therefore, the present study was carried out to evaluate operative outcomes, postoperative recovery and complications with the use of Hem-o-lok clips for closure of appendiceal stump.

## **Aim & Objectives**

### **Aims**

To assess the efficacy of Hem-o-lok clips for appendiceal stump ligation in laparoscopic appendectomy.

### **Objective**

1. To assess operative time of laparoscopic appendectomy using Hem-o-lok clips.
2. To evaluate the length of postoperative hospital stay.
3. To assess postoperative complications following appendiceal stump closure with Hem-o-lok clips.

## **MATERIALS AND METHODS**

### **Study Design**

Hospital-based prospective observational study.

### **Study Setting**

Department of Minimal Access and General Surgery, Government Medical College Srinagar.

### **Study Duration**

March 2024 to September 2025.

### **Study Population**

Thirty-six patients undergoing laparoscopic appendectomy with Hem-o-lok clip application for appendiceal stump closure.

### **Inclusion Criteria**

- Adults above 16 years
- Acute appendicitis
- Recurrent appendicitis
- Chronic appendicitis
- Patients consenting for laparoscopic appendectomy

### **Exclusion Criteria**

- Appendicular abscess
- Appendicular lump
- Appendicular perforation
- Pregnancy

- Gangrenous appendix involving base
- Refusal for consent

### Surgical Technique

Under general anesthesia, patients were positioned supine with Trendelenburg tilt and right side elevated. Pneumoperitoneum was established using carbon dioxide through a supraumbilical port. Additional 5-mm working ports were inserted in the right iliac fossa and suprapubic region.

The appendix was identified and mesoappendix dissected using harmonic scalpel. Hem-o-lok clips were applied at the appendiceal base using a clip applicator. Two clips were applied proximally and one distally, followed by division of the appendix between clips.

### Follow-Up

Patients were followed on postoperative day 7 and day 30.

### Statistical Analysis

Continuous variables were expressed as mean  $\pm$  SD. Categorical variables were represented as frequency and percentages. Statistical significance was considered at  $p < 0.05$ .

## RESULTS

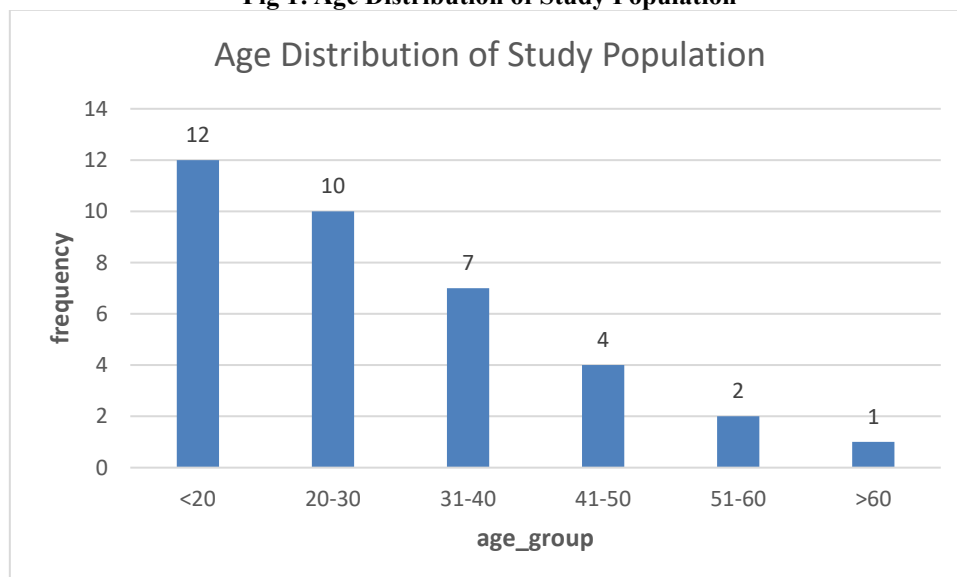
**Table 1: Age Distribution of Study Population**

Age Group (Years)	Frequency	Percentage
<20	12	33.3%
20–30	10	27.8%
31–40	7	19.4%
41–50	4	11.1%
51–60	2	5.6%
>60	1	2.8%

**Mean age:**  $30.14 \pm 13.47$  years

The majority of patients belonged to younger age groups, reflecting the classical epidemiological pattern of appendicitis occurring predominantly in young adults.

**Fig 1: Age Distribution of Study Population**

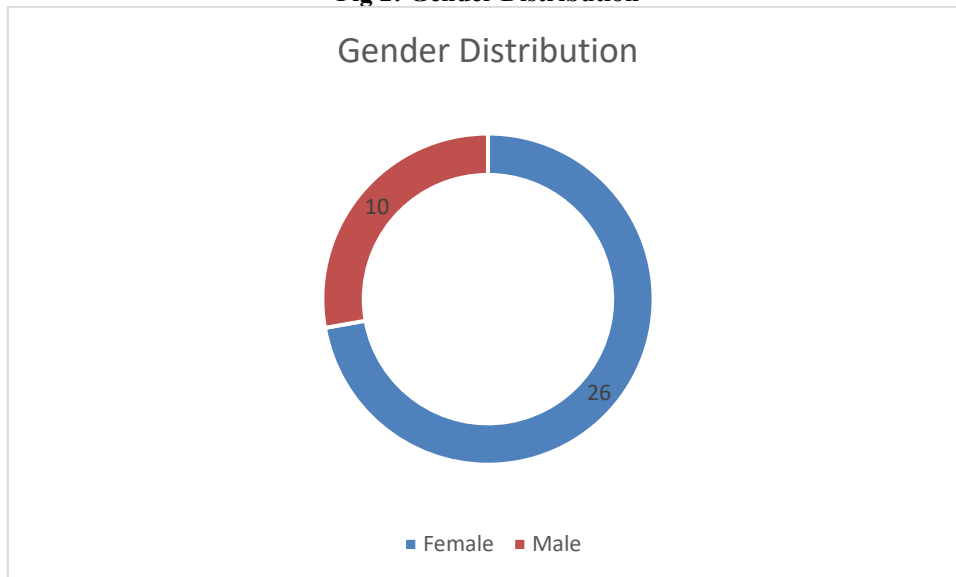


**Table 2: Gender Distribution**

Gender	Frequency	Percentage
Female	26	72.2%
Male	10	27.8%

Female patients constituted the majority of the study population with a female-to-male ratio of approximately 2.6:1.

**Fig 2: Gender Distribution**



**Table 3: Distribution of Comorbidities**

Comorbidity	Frequency	Percentage
No Comorbidity	30	83.3%
Hypothyroidism	4	11.1%
HTN + T2DM	1	2.8%
HTN + T2DM + Hypothyroidism	1	2.8%

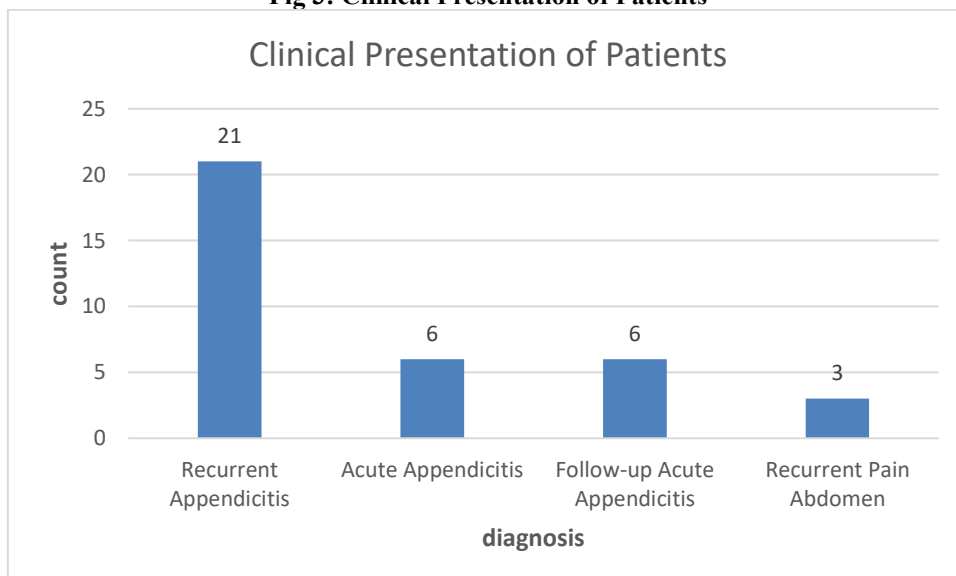
Most patients had no associated medical comorbidity. Hypothyroidism was the commonest associated illness.

**Table 4: Clinical Presentation**

Presentation	Frequency	Percentage
Recurrent Appendicitis	21	58.3%
Acute Appendicitis	6	16.7%
Follow-up Acute Appendicitis	6	16.7%
Recurrent Pain Abdomen	3	8.3%

Recurrent appendicitis represented the predominant clinical presentation, emphasizing the increasing recognition of recurrent inflammatory appendiceal disease.

**Fig 3: Clinical Presentation of Patients**



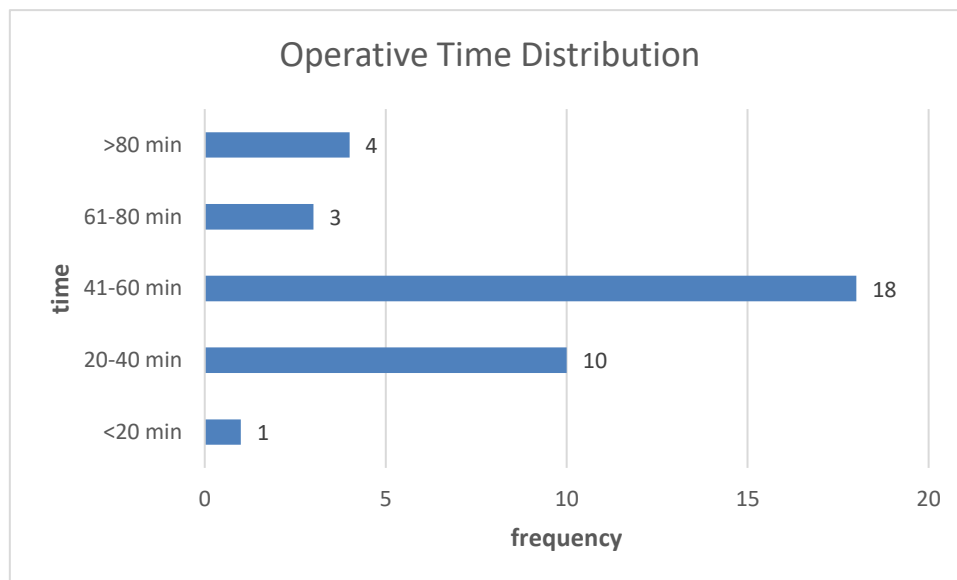
**Table 5: Operative Time Distribution**

Operative Time	Frequency	Percentage
<20 min	1	2.8%

20–40 min	10	27.8%
41–60 min	18	50.0%
61–80 min	3	8.3%
>80 min	4	11.1%

**Mean operative time:** 53.5 ± 21.5 minutes

The majority of surgeries were completed within 41–60 minutes. Longer operative durations were generally associated with dense adhesions, recurrent inflammation, or difficult anatomy.



### Interpretation of the Results

The results achieved in the present study demonstrate that laparoscopic appendectomy with Hem-o-lok clips is technically feasible and clinically effective. The predominance of younger patients is in line with the established epidemiology of appendicitis where lymphoid hyperplasia is more common in younger age groups [13].

The female predominance in this study might also be explained by increased healthcare utilization by female patients presenting with recurrent abdominal pain requiring diagnostic laparoscopy. The commonest presentation was recurrent appendicitis. This supports the concept that recurrent appendiceal inflammation is a significant clinical entity.

Mean operative time of 53.5 minutes compares well with the published literature. Hem-o-lok clips facilitated appendiceal stump closure, making it less technically demanding and allowing the operation to be completed quickly. The locking mechanism provided a sense of security that the stump was safe.

There were no major post-operative complications like stump leak, intra-abdominal abscess, fecal fistula or mortality. These findings strongly support the reliability of polymeric clips for appendiceal stump closure.

The lack of serious complications may be related to proper selection of patients, exclusion of perforated appendicitis, good visualization and safe application of clips. Hem-o-lok clips effectively sealed the appendiceal base with minimal tissue trauma.

### DISCUSSION

The improvement in postoperative results, early mobilization and better cosmetic outcome have led to laparoscopic appendectomy being the surgical treatment of choice for appendicitis. However, the best appendiceal stump closure is still an important determinant of post-operative morbidity. The objective of the present study was to evaluate the efficacy and safety of Hem-o-lok clips for appendiceal stump closure during laparoscopic appendectomy.

The mean age in the current study was 30.14 ± 13.47 years, which is comparable to the studies of Lucchi et al. and Kennedy et al., where most of the patients were young adults [14,15]. Appendicitis is common in the second and third decades because of increased activity of lymphoid tissue.

The female predominance observed in the present study contrasts with the classical epidemiological trends where males slightly predominate. Reinle et al. [16] reported similar female predominance. This disparity could be explained by referral patterns, health-seeking behavior or increased diagnostic workup in women presenting with right iliac fossa pain.

The most common clinical presentation was recurrent appendicitis. This finding highlights the growing recognition of recurrent appendiceal inflammation as an important surgical entity. Chronic low-grade inflammation can result in recurrent abdominal symptoms and ultimately in appendectomy.

The mean operative time in the present study was 53.5 minutes which is comparable to the results reported by Oz et al., Wilson et al., and Srikantgowda et al. [17–19]. The Hem-o-lok clips facilitate stump closure by obviating the need for intracorporeal knotting or repeated manipulation of loops. The lock provides security of application and reduces clip slip. Several comparative studies have shown shorter operative duration with hemolock clips as compared to endoloops. Poon et al. (systematic review and meta-analysis) demonstrated a significant reduction in operative time with the use of polymeric clips [20]. This is supported by the findings of this study.

One of the great concern regarding appendiceal stump closure techniques is the development of postoperative complications such as stump leak, intra abdominal abscess and wound infection. There were no major complications in the current series. Hue et al., Parlakgumus et al., and Christopher Soll et al. [21–23] reported similar results.

In this study, there was no stump leakage, which proves the reliability of the Hem-o-lok clips in securing the appendiceal stump. The integrated locking teeth prevent the clip from being displaced and provide enough compression at the base of the appendix. Also, there are polymeric, nonconductive and inert clips that reduce tissue reactivity.

Another important factor is cost effectiveness. Endoscopic staplers are reliable but increase the cost of the procedures significantly. Hem-o-lok clips are relatively cheap and easy to use. Significant cost reduction has been demonstrated using polymeric clips by authors such as Reinle et al. and Al-Temimi et al. [16,24].

The present study also demonstrated good post-operative recovery with less hospital stay and no mortality. Less tissue manipulation, smaller incisions and secure stump closure all contribute to quicker recovery after laparoscopic appendectomy.

The study has several strengths. The prospective design, the standardized surgical technique, and the systematic follow-up after surgery reinforced the study. But there are some limitations. Sample size was relatively small and there was no comparison group with other stump closure techniques (endoloop or stapler). Long term follow-up was not available beyond 30 days.

Despite these limitations, the results strongly support the use of Hem-o-lok clips as a safe and feasible method for appendiceal stump closure in laparoscopic appendectomy. Further validation of these results is recommended by larger randomized controlled trials comparing different closure techniques.

## CONCLUSION

The Hem-o-lok clip is a safe, effective and technically simple technique of appendiceal stump closure in laparoscopic appendectomy. They are accustomed to:

- Reduced operative complexity
- Adequate operating time
- Very low post-operative complication rate
- Good results from recovery
- Cost effectiveness

The study recommends the use of Hem-o-lok clips in laparoscopic appendectomy for wider use especially in resource-constrained settings where cost containment is of importance without compromising surgical safety.

## REFERENCES

1. Bhangu A, Søreide K, Di Saverio S, et al. Acute appendicitis: modern understanding of pathogenesis, diagnosis, and management. *Lancet*. 2015;386:1278-1287.
2. Ferris M, Quan S, Kaplan BS, et al. The global incidence of appendicitis. *Ann Surg*. 2017;266:237-241.
3. Semm K. Endoscopic appendectomy. *Endoscopy*. 1983;15:59-64.
4. Sauerland S, Jaschinski T, Neugebauer EA. Laparoscopic versus open surgery for suspected appendicitis. *Cochrane Database Syst Rev*. 2010;10:CD001546.
5. Gomes CA, Junior CS, de Peixoto RO, et al. Appendiceal stump closure by metal endoclip in laparoscopic appendectomy. *JLS*. 2013;17:647-651.
6. Delibegovic S. The use of Hem-o-lok clips in appendiceal stump closure. *Med Arch*. 2012;66:132-134.
7. Al-Temimi MH, Berglin MA, Kim EG, et al. Endostapler versus Hem-o-lok clips. *Surg Endosc*. 2017;31:5265-5271.
8. Lucchi A, Berti P, Grassia M, et al. Hem-o-lok clips versus endoloop. *Surg Laparosc Endosc Percutan Tech*. 2016;26:152-156.
9. Hue CS, Kim JS, Kim KH, et al. Safety of Hem-o-lok clips. *J Korean Surg Soc*. 2013;84:27-32.

10. Wilson MSJ, MacArthur DC, Hicks CW. Polymeric clips versus endoloops. *Ann R Coll Surg Engl.* 2018;100:237-242.
11. Knight SR, Ibrahim A, Makaram N, et al. Polymeric clips for appendiceal stump closure. *Int J Surg.* 2019;63:24-31.
12. Poon SHT, et al. Systematic review of Hem-o-lok clips. *Surg Endosc.* 2023;37:4210-4219.
13. Humes DJ, Simpson J. Acute appendicitis. *BMJ.* 2006;333:530-534.
14. Lucchi A, et al. Comparison of Hem-o-lok clips and endoloop. *Surg Endosc.* 2016;30:252-258.
15. Kennedy JJ, et al. Hem-o-lok versus Roeder's knot. *Cureus.* 2023;15:e38201.
16. Reinle CE, et al. Polymeric clips in laparoscopic appendectomy. *J Surg Res.* 2016;203:294-299.
17. Oz AB, et al. Safety and cost effectiveness of Hem-o-lok clips. *Wideochir Inne Tech Maloinwazyjne.* 2017;12:242-247.
18. Wilson MSJ, et al. Emergency laparoscopic appendectomy outcomes. *Ann R Coll Surg Engl.* 2018;100:237-242.
19. Srikantgowda M, et al. Polymeric clips versus endoloops. *Int Surg J.* 2025;12:122-129.
20. Poon SHT, et al. Meta-analysis of Hem-o-lok application. *Surg Endosc.* 2023;37:4210-4219.
21. Hue CS, et al. Safety of Hem-o-lok clip closure. *J Korean Surg Soc.* 2012;84:27-32.
22. Parlakgumus A, et al. Polymeric clip appendectomy outcomes. *Wideochir Inne Tech Maloinwazyjne.* 2017;12:143-149.
23. Soll C, et al. Polymeric clips versus staplers. *Surg Endosc.* 2019;33:2542-2549.
24. Al-Temimi MH, et al. Cost analysis of appendiceal stump closure. *Surg Endosc.* 2017;31:5265-5271.