



Original Article

Histopathological and Immunohistochemical Study of Endometrial Samples in Cases of Postmenopausal Bleeding

Dr. S. Monica¹, Dr. B. Kayalvizhi², Dr. Priyadarsini G³

¹Assistant professor, Department of Pathology, Dhanalakshmi Srinivasan institute of medical sciences, Thuraiyur road, Perambalur Tamil Nadu, India Phone: 9442528646, Email - drmonicaramprasad@gmail.com, Orcid id - 0009-0006-1430-7400

²Assistant professor, Department of Pathology, Dhanalakshmi Srinivasan institute of medical sciences, Thuraiyur road, Perambalur Tamil Nadu, India Phone: 9600527530, Email - drkayalvizhi94@gmail.com, Orcid id - 0009-0009-5164-0642

³Assistant professor, Department of Pathology, Govt. Sivagangai Medical College, Sivagangai. Phone – 7708930372; Email - dr.priyapsg@gmail.com; Orcid id – 0009-0007-6930-7878

OPEN ACCESS

Corresponding Author:

Dr. S. Monica

Assistant professor, Department of Pathology, Dhanalakshmi Srinivasan institute of medical sciences, Thuraiyur road, Perambalur Tamil Nadu, India Phone: 9442528646, Email - drmonicaramprasad@gmail.com

Received: 20-05-2026

Accepted: 03-06-2026

Available online: 30-06-2026

Copyright © International Journal of Medical and Pharmaceutical Research

ABSTRACT

Background & Objectives: Postmenopausal bleeding (PMB) is a significant symptom that requires comprehensive evaluation to exclude the possibility of endometrial malignancy. This study seeks to assess the incidence of different endometrial lesions associated with PMB and to analyze the immunohistochemical (IHC) profiles of endometrial malignancies.

Methods: A descriptive study was conducted over 18 months, analyzing 300 endometrial samples from women presenting with PMB. Samples were evaluated histopathologically using Hematoxylin and Eosin (H&E) staining. Twenty-eight malignant cases were further subjected to IHC utilizing a panel comprising of ER, Vimentin, p53, and AMACR markers.

Results: The mean age of the participants was 53.87 ± 7.06 years. Histopathological examination revealed benign lesions in 81.7% of cases, malignant lesions in 10.7%, and inadequate samples in 7.7%. Among benign lesions, atrophic endometrium (31.8%) and endometrial polyp (28.6%) were the most frequent. Endometrioid endometrial adenocarcinoma was the predominant malignancy (81.3% of malignant cases). On IHC, 100% of endometrioid adenocarcinoma (Grades I and II) exhibited strong positivity for ER and Vimentin, and were negative for p53. One clear-cell carcinoma case demonstrated intense AMACR positivity, while one serous carcinoma showed diffuse block positivity for p53.

Interpretation & Conclusions: Although most cases of PMB are caused by benign conditions, the notable occurrence of malignancies highlights the importance of histopathological assessment. Immunohistochemistry (IHC) is a crucial tool for accurately classifying and grading endometrial carcinomas.

Keywords: Postmenopausal bleeding, Endometrial carcinoma, Immunohistochemistry.

INTRODUCTION

One of the most commonly presenting clinical complaint among postmenopausal women is bleeding (PMB), which causes great concern because of its strong link with the endometrial carcinoma^[1]. The natural phenomenon of cessation of ovulation and decreased hormone production results in atrophy of the endometrium. Bleeding from the vagina occurring after 12 months from the beginning of menopause should be considered as abnormal and requires an urgent investigation^[2,3].

Causes of bleeding vary from non neoplastic conditions such as atrophic endometrium, polyps, and simple hyperplasia to frank malignancy^[4,5]. Even though about 80% of the cases are related to benign changes, PMB is the main symptom

observed in 90% of patients with endometrial carcinoma^[6]. Endometrial polyps and hyperplasia can cause similar symptoms that also require early diagnosis^[7].

A biopsy test, preferably outpatient one, still remains the golden diagnostic method of choice regarding endometrial lesions^[8]. The development of the immuno-histochemistry (IHC) technique increased diagnostic and differential diagnostic ability drastically. Endometrioid carcinomas usually are stained positive for Estrogen receptors (ER), Progesterone Receptors (PR), and Vimentin; while more than 90% of serous carcinomas have All or None expression of p53^[9,10]. This research project aimed to study the histopathology of endometrium and IHC profile of diagnosed malignancies.

MATERIAL AND METHODS

The study was carried out by means of a descriptive study design with an overall study population of 300 patients. Non-probability consecutive sampling technique was employed, wherein all the endometrial samples available at our Department of Pathology, Government Medical College during the entire 18 months of study period, starting from April 2021 and ending October 2022, were included. The strict inclusion criterion for this study was the inclusion of only such endometrial samples as those which belong to postmenopausal women who presented with bleeding. To ensure adherence to the demographic scope of the study, endometrial samples of women in their premenopausal stage of life were not considered in the current study. The study protocol was reviewed and approved by our Institutional Ethics Committee. The research was conducted in full compliance with standard ethical guidelines for clinical and pathological studies, ensuring proper clearance before analyzing the patient samples collected during the study period from April 2021 to October 2022. Endometrial samples were obtained via endometrial biopsy (53.7%), total abdominal hysterectomy with bilateral salphingo-oophorectomy (TAH+BSO) (37.3%), fractional curettage, and other surgical procedures. Tissue specimens were fixed in 10% neutral buffered formalin, routinely processed, and embedded in paraffin wax. Sections of 4-micrometer thickness were stained with Hematoxylin and Eosin (H&E) for morphological diagnosis. Stringent quality controls were applied in the process of tissue processing and interpretation. All the samples of the endometrial tissues collected were equally treated through fixation in 10% formalin, processing, and embedding in paraffin for sectioning and staining. In carrying out immunohistochemistry on the tissues, the process adopted the technique of antigen retrieval by heat treatment. Immunohistochemistry markers' interpretations adhered to a specified procedure; for example, the determination of estrogen receptor status (ER) was done using the Allred scoring technique that involved proportion and intensity.

Twenty-eight samples diagnosed with malignancy were subjected to IHC study using the Heat Induced Epitope Retrieval (HIER) method. The marker panel included ER, Vimentin, p16, AMACR, and p53. The ER status was interpreted using the Allred scoring system, which combines the percentage of positive cells (Proportion Score, 0-5) and the intensity of the reaction (Intensity Score, 0-3). Scores between 3 and 8 were considered positive. Vimentin positivity was defined by strong cytoplasmic and membrane staining, p16 by strong and diffuse block positivity, p53 by all or none pattern and AMACR by cytoplasmic granular positivity.

RESULTS

The age of the study participants ranged from 45 to 90 years, with a mean age of 53.87 ± 7.06 years. The majority of patients (44.3%) were in the 45-50 years age group. On histopathological examination, benign lesions were predominant, accounting for 245 cases (81.7%). Malignant lesions were found in 32 cases (10.7%), and 23 samples (7.7%) were inadequate for reporting.

Table 1: Histopathological Diagnosis of Endometrial Samples

Histopathological Category	Frequency (n=300)	Percentage (%)
Benign Lesions	245	81.7
Atrophic endometrium	78	26.0
Endometrial polyp	70	23.3
Proliferative endometrium	43	14.3
Endometrial hyperplasia without atypia	29	9.6
Endometrial hyperplasia with atypia	10	3.3
Disordered proliferative endometrium	10	3.3
Endometritis	5	1.6
Malignant Lesions	32	10.7
Endometrioid adenocarcinoma	26	8.6
Squamous cell carcinoma of cervix	3	1.0
Carcinosarcoma	1	0.3
Clear cell carcinoma	1	0.3
Serous carcinoma	1	0.3

Inadequate for Diagnosis	23	7.6
--------------------------	----	-----

Age distribution correlated with the type of lesion: benign lesions were most common in the younger age group (40-50 years), while the incidence of malignant lesions peaked in the 51-60 years age group (68.8% of all malignancies).

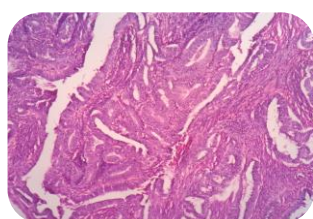
Immunohistochemical Profile

Twenty-eight malignant samples were analyzed using IHC (Table 2). Of the 26 endometrioid adenocarcinoma (EEA) cases, 20 were Grade I and 6 were Grade II. All EEA cases demonstrated 100% strong positivity for ER and Vimentin, and complete negativity for p53.

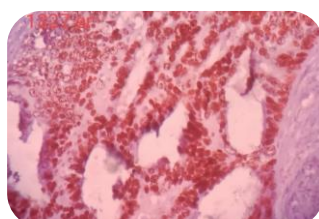
The single case of clear cell carcinoma showed intense, diffuse granular cytoplasmic positivity for AMACR, while testing negative for ER, Vimentin, and p53. The serous carcinoma case exhibited all or None staining pattern for p53, consistent with mutated Tp53, and lacked expression of the other markers.

Table 2: Immunohistochemical Marker Profile of Analyzed Malignancies (n=28)

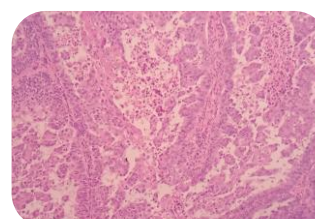
Diagnosis	Grade	ER	Vimentin	p53	AMACR
Endometrioid Adenocarcinoma (n=20)	I	Positive (100%)	Positive (100%)	Negative	Negative
Endometrioid Adenocarcinoma (n=6)	II	Positive (100%)	Positive (100%)	Negative	Negative
Clear Cell Carcinoma (n=1)	High	Negative	Negative	Negative	Positive
Serous Carcinoma (n=1)	High	Negative	Negative	Positive	Negative



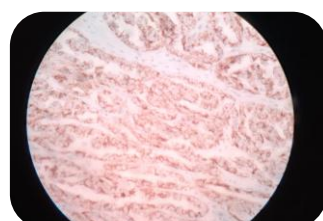
Endometrioid Adenocarcinoma showing back to back malignant glands with stratified nuclei with prominent nucleoli



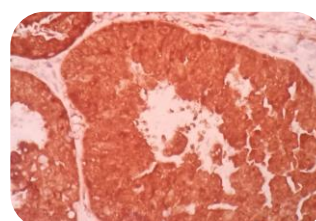
Endometrioid Adenocarcinoma showing Strong nuclear positivity in malignant endometrial glands by ER marker



Serous Carcinoma shows papillary and micropapillary pattern



Clear Cell Carcinoma showing intense granular cytoplasmic positivity by AMACR in tumor cells



Serous Carcinoma showing Diffuse intense Positivity for p53 in malignant glands

Figure 1 Histopathology and Immunohistochemistry of various samples

DISCUSSION

Postmenopausal bleeding is one of the important symptom of an underlying malignancy, hence, the need for a high index of suspicion in diagnosis. In our study, the mean age at diagnosis was 53.87 years, which is almost equal to the age of 53.22 years recorded by Vijayakumar et al.^[4], while the age of Mallick et al.^[5] is higher at 57.12 years.

Non neoplastic lesions were identified in 81.7% of our patients. The atrophic endometrium was found in 31.8% of those cases; this finding corresponds well with postmenopausal physiology since deprivation of estrogen results in atrophy of glands. Atrophic endometrium has a similar prevalence of 32% according to Srivatsa et al.,^[13] but it is much less compared to the prevalence of 40.7% documented by Mallick et al.^[5]. The endometrial polyp, accounting for 28.6% of the benign conditions, was much more prevalent than the only 4.6% recorded by Mallick et al.^[5]

Endometrial malignancy was seen in 10.7% of the cases. This incidence is similar to Srivatsa et al.'s study (10.4%), whereas Mallick et al. document a prevalence of 52.8%.^[5,13] Most endometrial malignancies diagnosed in our study had endometrioid morphology (81.3%).

It is necessary to distinguish between type I and type II endometrial cancers based on the different molecular mechanisms involved in their pathogenesis. Immunohistochemical staining showed that type I endometrial adenocarcinoma was negative for p53 but positive for ER and vimentin, a result that agrees with current literature^[14]. Type II serous endometrial carcinoma stained positively for p53, indicating a mutated TP53 protein, thus, distinguishing this carcinoma from the others. Clear cell endometrial carcinoma showed a strong positivity for AMACR protein^[15].

Strengths of the Study

The main strength of this research is a large sample size consisting of 300 women who are postmenopausal, making it highly representative with respect to the range of histopathological changes associated with endometrial lesions in this population group. In addition, the methodological design of the study transcends mere identification through a combination of an extensive array of immunochemistry (ER, Vimentin, p53, p16, AMACR) in all 28 types of malignant cases. This feature of IHC adds a lot to the diagnostic power of this research, providing a clear distinction between various endometrial carcinomas.

Limitations of the Study

Though the study is robust, there are a few limitations that the study is subject to. First, being a descriptive study done in a government medical college, the results may only be applicable to a particular demographic within the community. Secondly, out of the 300 samples used in the study, 23 of them (7.7%) were deemed unsuitable for histopathology report. Thirdly, though there were many samples in total, the number of each type of high-grade malignancy, which included clear cell carcinoma, serous carcinoma, and carcinosarcoma, was very low (each with one sample).

CONCLUSION

Most common cause of postmenopausal bleeding is non neoplastic conditions, which mainly include atrophic endometrium. Nevertheless, due to the fact that malignancy is associated with the aging process, it becomes imperative to conduct histopathologic evaluation for all such cases. Endometrioid adenocarcinoma is the type of malignancy frequently observed. Immunohistochemistry, which includes ER, vimentin, p53, and AMACR, plays a key role in subtyping such lesions.

REFERENCES

1. Kurman RJ, editor. Blaustein's Pathology of the Female Genital Tract [Internet]. New York, NY: Springer; 1994 [cited 2026 Jun 18]. Available from: <https://link.springer.com/10.1007/978-1-4757-3889-6> doi:10.1007/978-1-4757-3889-6
2. Patrizi L, Ticconi C, Borelli B, Finocchiaro S, Chiaramonte C, Sesti F, et al. Clinical significance of endometrial abnormalities: an observational study on 1020 women undergoing hysteroscopic surgery. *BMC Womens Health*. 2022;22(1):106. doi:10.1186/s12905-022-01682-5 PubMed PMID: 35392892; PubMed Central PMCID: PMC8991822.
3. Doraiswami S, Johnson T, Rao S, Rajkumar A, Vijayaraghavan J, Panicker VK. Study of endometrial pathology in abnormal uterine bleeding. *J Obstet Gynaecol India*. 2011;61(4):426–30. doi:10.1007/s13224-011-0047-2 PubMed PMID: 22851826; PubMed Central PMCID: PMC3295868.
4. Vijayakumar S, Sinha P, Krishnamurthy D. Histomorphological Spectrum of Cervical Lesions in a Rural Hospital. *Cureus*. 13(9):e18293. doi:10.7759/cureus.18293 PubMed PMID: 34722069; PubMed Central PMCID: PMC8547380.
5. Mallick A, Behera R, Subudhi K. Histopathological study of endometrium in postmenopausal bleeding. *Journal of Evolution of Medical and Dental Sciences* [Internet]. 2013 [cited 2026 Jun 18];2(46):9010-. Located at: Gale OneFile: Health and Medicine. Available from: <https://link.gale.com/apps/doc/A362963025/HRCA?sid=googleScholar&xid=246a7ade>

6. Bani Lrshaid I, Al Sumadi A. Histological findings in women with postmenopausal bleeding: Jordanian figures. *East Mediterr Health J.* 2011;17(07):582–6. doi:10.26719/2011.17.7.582
7. Anastasiadis PG, Koutlaki NG, Skaphida PG, Galazios GC, Tsikouras PN, Liberis VA. Endometrial polyps: prevalence, detection, and malignant potential in women with abnormal uterine bleeding. *Eur J Gynaecol Oncol.* 2000;21(2):180–3. PubMed PMID: 10843481.
8. Clark TJ, Mann CH, Shah N, Khan KS, Song F, Gupta JK. Accuracy of outpatient endometrial biopsy in the diagnosis of endometrial hyperplasia. *Acta Obstet Gynecol Scand.* 2001;80(9):784–93. doi:10.1034/j.1600-0412.2001.080009784.x PubMed PMID: 11531627.
9. Chiang S, Soslow RA. Updates in diagnostic immunohistochemistry in endometrial carcinoma. *Semin Diagn Pathol.* 2014;31(3):205–15. doi:10.1053/j.semdp.2014.03.002 PubMed PMID: 24951284.
10. Halperin R, Zehavi S, Habler L, Hadas E, Bukovsky I, Schneider D. Comparative immunohistochemical study of endometrioid and serous papillary carcinoma of endometrium. *Eur J Gynaecol Oncol.* 2001;22(2):122–6. PubMed PMID: 11446475.
11. Amant F, Cadron I, Fuso L, Berteloot P, de Jonge E, Jacomen G, et al. Endometrial carcinosarcomas have a different prognosis and pattern of spread compared to high-risk epithelial endometrial cancer. *Gynecol Oncol.* 2005;98(2):274–80. doi:10.1016/j.ygyno.2005.04.027 PubMed PMID: 15972232.
12. Sahin EA, Toprak S, Sayal HB, Ekinci T, Yilmaz E, Bakay K, et al. Analysis of prognostic factors in Grade 3 endometrioid type endometrial carcinoma. *Int J Gynaecol Obstet.* 2022;159(3):719–26. doi:10.1002/ijgo.14277 PubMed PMID: 35598153.
13. M H P, Girija G, S Hiremath S. HISTOPATHOLOGICAL SPECTRUM OF ENDOMETRIAL LESIONS IN TERTIARY CARE CENTRE- A PROSPECTIVE STUDY. Govind Miraj S, editor. *ijsr.* 2023;56–9. doi:10.36106/ijsr/2608073
14. Kounelis S, Kapranos N, Kouri E, Coppola D, Papadaki H, Jones MW. Immunohistochemical profile of endometrial adenocarcinoma: a study of 61 cases and review of the literature. *Mod Pathol.* 2000;13(4):379–88. doi:10.1038/modpathol.3880062 PubMed PMID: 10786803.
15. Zannoni GF, Santoro A, Angelico G, Spadola S, Arciuolo D, Valente M, et al. Clear cell carcinoma of the endometrium: an immunohistochemical and molecular analysis of 45 cases. *Hum Pathol.* 2019;92:10–7. doi:10.1016/j.humphath.2019.06.005 PubMed PMID: 31269413.