



Case Report

LEFT ATRIAL MYXOMA WITH ATYPICAL PRESENTATION AS ACUTE CEREBROVASCULAR ACCIDENT: A CASE REPORT

Dr. Katari Subash¹, Dr. Kosa Raju kamalakar², Dr. John Satish R³, Dr. Krishna Prasad N⁴, Dr. Ravi Teja V⁵

¹ Assistant professor, Department of Cardiology, NRI Institute of medical science, Chinna kakani, Guntur

²⁻⁵ Department of Cardiology, NRI Institute of medical science, Chinna kakani, Guntur

 OPEN ACCESS

Corresponding Author:

Dr. Katari Subash

Assistant professor, Department of Cardiology, NRI Institute of medical science, Chinna kakani, Guntur.

Received: 24-04-2026

Accepted: 28-05-2026

Available online: 17-06-2026

Copyright © International Journal of Medical and Pharmaceutical Research

ABSTRACT

Left atrial myxoma is the most common primary cardiac tumor, accounting for nearly 80% of benign cardiac tumors. Clinical presentation varies widely depending upon tumor size, mobility, and embolic potential. Neurological manifestations due to systemic embolization are uncommon but clinically significant presentations. We report a rare case of a 40 year-old female who presented with acute cerebrovascular accident and exertional dyspnea, later diagnosed with a large left atrial myxoma attached to the interatrial septum. Coronary angiography additionally demonstrated vascular supply to the tumor from the right coronary artery branch. The patient underwent successful surgical excision with favorable postoperative outcome.

Keywords: Left atrial myxoma, cerebrovascular accident, embolic stroke, cardiac tumor, echocardiography, coronary angiography.

INTRODUCTION

Cardiac myxoma is the most common primary benign cardiac neoplasm. Approximately 75–85% of myxomas arise in the left atrium, commonly originating from the fossa ovalis region of the interatrial septum. Although histologically benign, these tumors may produce severe complications due to obstruction, embolization, or constitutional manifestations.

Clinical manifestations are variable and may mimic valvular heart disease, infective endocarditis, vasculitis, or cerebrovascular disease. Neurological complications resulting from embolization occur in approximately 20–35% of patients and may be the initial presentation.

This case highlights an atypical presentation of left atrial myxoma presenting primarily as ischemic stroke with additional unusual angiographic finding of tumor vascularity from the right coronary artery.

CASE PRESENTATION

40year female patient presented with complaints of weakness of the left upper limb and left lower limb associated with dysarthria for one week duration. She was evaluated for acute cerebrovascular accident.

CT brain demonstrated acute non-hemorrhagic infarct involving the right parietal region. She was initiated on antiplatelet agents and statins.

The patient also complained of progressive breathlessness on exertion for the past 2–3 months, which worsened while sitting upright. There was no history of chest pain, palpitations, syncope, fever, weight loss, or constitutional symptoms. She was not a known case of diabetes mellitus, hypertension, or thyroid disease.

CLINICAL EXAMINATION

On examination, the patient was conscious and coherent with Glasgow Coma Scale score of 15/15.

General examination revealed:

- No pallor
- No icterus
- No cyanosis
- No clubbing
- No lymphadenopathy

Cardiovascular examination:

- Apical impulse palpable in left 5th intercostal space medial to midclavicular line
- S1 and S2 normal
- No murmurs or additional sounds

Respiratory system:

- Bilateral normal vesicular breath sounds

Central nervous system examination:

- Left hemiparesis
- Left upper limb power: 4/5
- Left lower limb power: 3/5
- Left extensor plantar response

INVESTIGATIONS

Electrocardiography

ECG demonstrated:

- Normal sinus rhythm
- Left atrial enlargement
- No ST-T changes

Echocardiography

Transthoracic echocardiography revealed:

- Large left atrial myxoma attached to the interatrial septum
- Normal left ventricular systolic function
- Ejection fraction: 60%
- Grade I left ventricular diastolic dysfunction
- No regional wall motion abnormalities
- No intracardiac clot
- No pericardial effusion

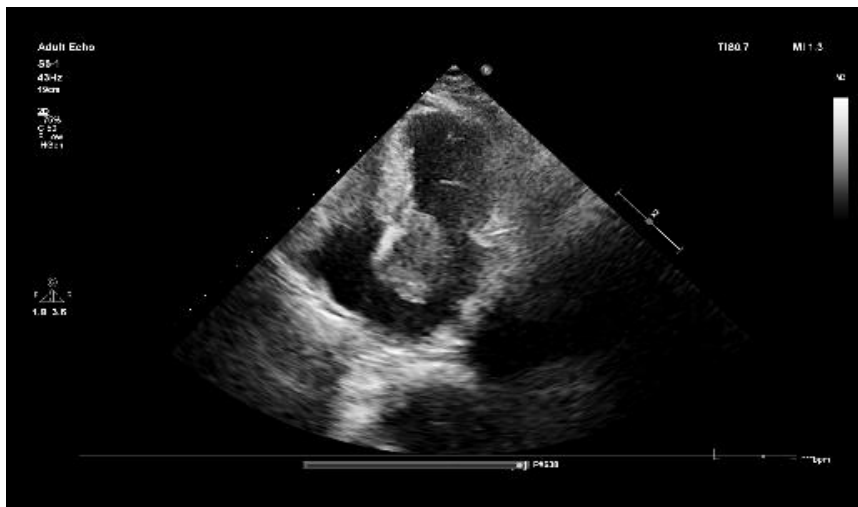


Figure 1: Apical four-chamber echocardiographic view demonstrating large left atrial myxoma attached to interatrial septum.

Carotid Doppler

Carotid Doppler demonstrated atherosclerotic changes without significant luminal obstruction.

Coronary Angiography

Coronary angiography revealed mild coronary artery disease. Interestingly, vascular supply to the left atrial myxoma was visualized arising from a branch of the right coronary artery. This finding supported the diagnosis of a vascular cardiac tumor and aided preoperative planning.

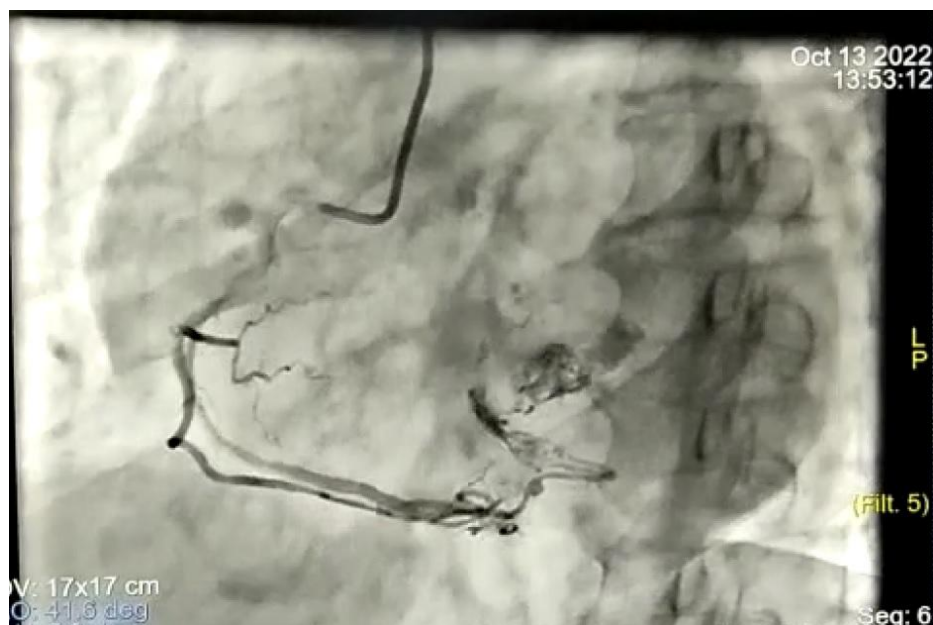

Figure 2: Coronary angiography demonstrating vascular supply to left atrial myxoma from right coronary artery branch.

DIFFERENTIAL DIAGNOSIS

The differential diagnoses considered included:

- Left atrial thrombus
- Infective endocarditis with vegetation
- Cardiac papillary fibroelastoma
- Intracardiac metastatic lesion
- Mitral valve pathology

TREATMENT

The patient was referred to the cardiothoracic surgery department for surgical excision of the tumor. Complete excision of the left atrial myxoma was successfully performed. Postoperative recovery was uneventful, and the patient remained hemodynamically stable.

SPECIMEN

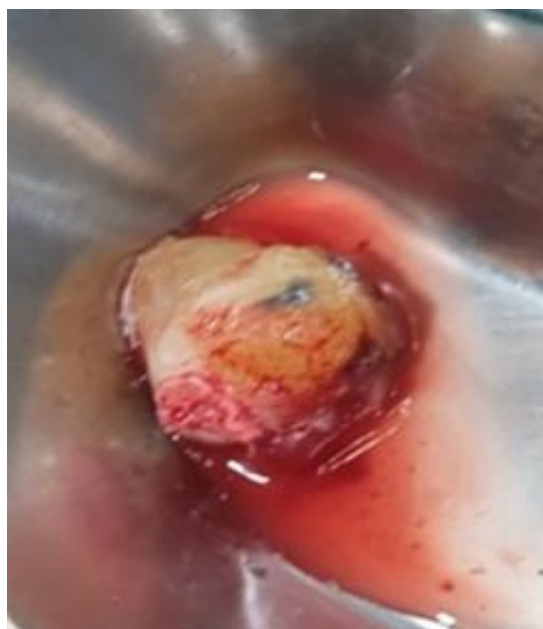

Figure 3: Gross specimen of excised left atrial myxoma.

DISCUSSION

Cardiac myxomas are rare tumors with an annual incidence of approximately 0.5 per million population. They occur more commonly in females and are usually diagnosed between 40 and 60 years of age.

Approximately 85% of myxomas are pedunculated and arise from the interatrial septum near the fossa ovalis. Villous or papillary forms are particularly fragile and have higher embolic potential.

The classic triad of presentation includes:

1. Obstructive cardiac symptoms
2. Embolic manifestations
3. Constitutional symptoms

Embolic phenomena may involve cerebral, retinal, coronary, renal, or peripheral arteries. Cerebral embolization is among the most feared complications and may lead to ischemic stroke.

Our patient presented predominantly with neurological manifestations, emphasizing the importance of echocardiographic evaluation in embolic stroke patients without obvious vascular etiology.

The angiographic finding of tumor vascularity arising from the RCA branch is uncommon but has been described in literature. Coronary angiography prior to surgery helps identify concomitant coronary artery disease and tumor neovascularization.

Echocardiography remains the gold standard diagnostic modality with high sensitivity and specificity. Definitive management is prompt surgical excision because of risk of sudden obstruction and recurrent embolization.

CONCLUSION

Left atrial myxoma should be considered in patients presenting with embolic stroke associated with unexplained dyspnea or positional symptoms with Normal sinus Rhythm on Ecg in younger patients. Early echocardiographic evaluation is essential for diagnosis. Surgical excision remains curative and prevents recurrent embolic complications.

LEARNING POINTS

- A young patient presented with an embolic stroke in the absence of conventional cerebrovascular risk factors. ECG demonstrated normal sinus rhythm. The possibility of a cardiac source of embolism, particularly left atrial myxoma, should be considered
- Cardiac myxoma may present initially as ischemic stroke.
- Echocardiography is essential in evaluation of embolic stroke of unclear etiology.
- Coronary angiography may demonstrate tumor neovascularization.
- Early surgical intervention provides excellent prognosis.

REFERENCES

1. Reynen K. Cardiac myxomas. *N Engl J Med.* 1995;333:1610-1617.
2. Keeling IM, Oberwalder P, Anelli-Monti M, et al. Cardiac myxomas: 24 years of experience in 49 patients. *Eur J Cardiothorac Surg.* 2002;22:971-977.
3. Pinede L, Duhaut P, Loire R. Clinical presentation of left atrial cardiac myxoma. *Medicine (Baltimore).* 2001;80:159-172.
4. Burke A, Virmani R. Cardiac myxoma: a clinicopathologic study. *Am J Clin Pathol.* 1993;100:671-680.
5. Bjessmo S, Ivert T. Cardiac myxoma: 40 years' experience. *Ann Thorac Surg.* 1997;63:697-700.