



Original Article

## Arcuate Foramen of the Atlas Vertebra: A Morphological Osteological Study with Clinical Significance

Sumit Suman<sup>1</sup>, Md. Anamul Haque<sup>2</sup>, Rekha Kumari<sup>3</sup>, Pramod Kumar<sup>1</sup>, Rajeev Ranjan<sup>1</sup>, Birju Bharti<sup>1</sup>, Khushboo Rani<sup>1</sup>, Nishu Priya<sup>1</sup>

<sup>1</sup>Junior Resident, Department of Anatomy, Bhagwan Mahavir Institute of Medical Sciences, Pawapuri, Bihar (India).

<sup>2</sup>Senior Resident, Department of Anatomy, Bhagwan Mahavir Institute of Medical Sciences, Pawapuri, Bihar (India).

<sup>3</sup>Associate Professor and Head, Department of Anatomy, Bhagwan Mahavir Institute of Medical Sciences, Pawapuri, Bihar (India).

OPEN ACCESS

### Corresponding Author:

**Md. Anamul Haque**

Senior Resident,  
Department of Anatomy,  
Bhagwan Mahavir Institute of  
Medical Sciences,  
Pawapuri, Bihar (India).

Email ID:

[drmahaque1990@gmail.com](mailto:drmahaque1990@gmail.com)

Received: 15-04-2026

Accepted: 25-04-2026

Available online: 08-06-2026

Copyright © International Journal of  
Medical and Pharmaceutical Research

### ABSTRACT

**Background:** The arcuate foramen (ponticulus posticus) is a common anatomical variation of the atlas vertebra formed by ossification of the posterior atlanto-occipital membrane over the groove for the vertebral artery. Its presence may have important clinical implications because of its close relationship with the vertebral artery and surrounding neurovascular structures.

**Materials And Methods:** This descriptive cross-sectional osteological study was conducted on 50 dry adult human atlas vertebrae obtained from the Department of Anatomy, Bhagwan Mahavir Institute of Medical Sciences, Pawapuri, Bihar. Each vertebra was examined for the presence of an arcuate foramen and classified as complete or incomplete. The side of occurrence was recorded, and morphometric measurements of complete arcuate foramina were obtained using a digital vernier calliper. Data were analysed using descriptive statistics.

**Results:** Arcuate foramen was observed in 12 of 50 atlas vertebrae (24%), while 38 specimens (76%) showed no bony bridging. Incomplete arcuate foramina were more common than complete forms. Both complete and incomplete forms occurred as unilateral and bilateral variants, with unilateral presentation being more common. Morphometric analysis of complete arcuate foramina revealed a mean anteroposterior diameter of  $9.13 \pm 1.05$  mm and a mean superoinferior diameter of  $8.01 \pm 0.98$  mm. These findings indicate that the arcuate foramen is a relatively common anatomical variation of the atlas vertebra, with incomplete forms occurring more frequently than complete forms.

**Conclusion:** The arcuate foramen represents a clinically significant anatomical variation of the atlas vertebra. Awareness of its occurrence and morphology is important during radiological assessment and surgical procedures involving the craniovertebral junction to reduce the risk of vertebral artery injury and associated complications.

**Keywords:** Arcuate foramen, Atlas vertebra, Cervical vertebra, Morphological variation, Vertebral artery.

### INTRODUCTION

The atlas (C1) is the first cervical vertebra and plays a crucial role in supporting the skull and permitting extensive movements of the head and neck. Structurally, it differs from the remaining cervical vertebrae by the absence of a vertebral body and spinous process. Instead, it consists of anterior and posterior arches connected by two lateral masses. The anterior arch articulates with the dens of the axis, whereas the superior articular facets of the lateral masses articulate with the occipital condyles, forming the atlanto-occipital joints. The posterior arch, representing the homologous structure of the vertebral laminae, constitutes the major portion of the atlantal ring and contributes significantly to the stability of the craniovertebral region [1]. A distinct groove for the vertebral artery, known as the sulcus arteriae vertebralis, is located on the superior aspect of the posterior arch near the lateral mass. This groove transmits the third segment of the vertebral artery along with the accompanying venous plexus and the suboccipital nerve. The posterior atlanto-occipital membrane attaches to the superior margin of the posterior arch. In certain individuals, ossification of the free lateral edge of this

membrane or the oblique atlanto-occipital ligament results in the formation of a bony bridge over the vertebral artery groove, converting it into a canal-like opening termed the arcuate foramen [2]. This anatomical variant has been described by several names in the literature, including ponticulus posticus, ponticulus posterior, retroarticular canal, retroarticular vertebral artery ring, posterior atlantoid foramen, atlas bridging, canalis arteriae vertebralis, foramen retroarticulare superior, pons posticus, Kimmerle anomaly, and various other synonymous terms [3]. The arcuate foramen is among the most frequently encountered anatomical variations of the atlas and may occur either unilaterally or bilaterally, as well as in complete or incomplete forms. After emerging from the transverse foramen of the atlas, the vertebral artery courses posteriorly across the superior surface of the posterior arch before entering the cranial cavity through the foramen magnum. Because of this intimate anatomical relationship, any osseous alteration in this region may influence the course of the artery. Occasionally, a secondary osseous bridge extending from the lateral mass towards the posterior root of the transverse process forms a structure known as the ponticulus lateralis. When both posterior and lateral bridges coexist, they may create a complete tunnel enclosing the vertebral artery [4]. The vertebral artery is particularly susceptible to compression and mechanical stress while traversing the craniovertebral junction. Bony bridges associated with the arcuate foramen may exert pressure on the artery and compromise vertebrobasilar circulation, especially during excessive rotation or extension of the head and neck [5]. Such vascular compromise has been implicated in a variety of clinical manifestations, including dizziness, vertigo, headache, migraine, visual disturbances, neck pain, hearing impairment, Barré-Liéou syndrome, and occasionally transient episodes of loss of consciousness [6,7]. Furthermore, forceful cervical manipulations may accentuate vascular compression by reducing the luminal diameter of the vertebral artery, thereby precipitating symptoms related to vertebrobasilar insufficiency [8]. Recognition of the arcuate foramen is therefore of considerable importance to anatomists, radiologists, neurosurgeons, orthopaedic surgeons, and clinicians involved in the management of cervical spine disorders. Failure to identify this variation during radiological assessment or surgical planning may increase the likelihood of vertebral artery injury, particularly during procedures such as posterior C1 lateral mass screw fixation and other interventions involving the craniovertebral junction [9,10]. Although the prevalence and morphology of the arcuate foramen have been investigated in numerous populations worldwide, information regarding its occurrence in the Bihar population remains limited. Therefore, the present osteological study was designed to determine the incidence and morphological patterns of the arcuate foramen in dry human atlas vertebrae and to highlight its potential clinical significance in relation to vertebral artery entrapment and craniovertebral surgical procedures.

#### **MATERIALS AND METHODS:**

This descriptive cross-sectional osteological study was carried out in the Department of Anatomy, Bhagwan Mahavir Institute of Medical Sciences, Pawapuri, Bihar. The study aimed to determine the incidence, morphological variations, and morphometric features of the arcuate foramen in human atlas vertebrae and to evaluate its clinical relevance. A total of 50 dry adult atlas (C1) vertebrae were collected from the osteological repository of the Department of Anatomy. The specimens were of unknown age and sex and were routinely maintained for teaching and research purposes.

**Study Sample:** The sample size was based on the number of suitable atlas vertebrae available in the departmental collection. All specimens that fulfilled the inclusion criteria were included in the study. Consequently, 50 atlas vertebrae were examined, allowing assessment of the prevalence and morphological characteristics of the arcuate foramen in the available sample.

#### **Inclusion Criteria**

The following specimens were included in the study:

- Fully ossified adult atlas vertebrae.
- Vertebrae with intact posterior arches and lateral masses.
- Specimens without visible pathological changes or deformities.

#### **Exclusion Criteria**

The following specimens were excluded from the study:

- Fractured or damaged atlas vertebrae.
- Vertebrae showing congenital abnormalities involving the posterior arch.
- Specimens with erosions, pathological lesions, or excessive wear that could affect observations or measurements.

Each vertebra was examined visually after careful cleaning. The superior surface of the posterior arch was inspected for the presence of a bony bridge over the vertebral artery groove (sulcus arteriae vertebralis). The presence and morphological pattern of the arcuate foramen were recorded.

Based on morphology, the arcuate foramina were classified as:

- **Complete Arcuate Foramen:** A fully ossified bony bridge enclosing the vertebral artery groove and forming a complete foramen.
- **Incomplete Arcuate Foramen:** A partially ossified bridge that did not completely convert the groove into a foramen.

The arcuate foramina were further classified according to laterality as right unilateral, left unilateral, or bilateral. For bilateral arcuate foramina, each vertebra was considered as a single specimen for prevalence analysis. All findings were

documented in a predesigned data collection sheet. Morphometric analysis was performed on vertebrae showing a complete arcuate foramen. Measurements were obtained using a digital vernier calliper with an accuracy of 0.01 mm.

The following parameters were recorded:

1. Anteroposterior Diameter (APD): Maximum distance between the anterior and posterior margins of the arcuate foramen.
2. Superoinferior Diameter (SID): Maximum vertical distance between the superior and inferior margins of the arcuate foramen.

All measurements were recorded in millimetres (mm), and care was taken to reduce measurement errors.

### Statistical Analysis

The collected data were entered into tables and analysed using descriptive statistics. The frequency and percentage of complete and incomplete arcuate foramina, along with their side-wise distribution, were calculated. Morphometric data were expressed as mean  $\pm$  standard deviation. Statistical analysis was carried out using IBM SPSS software for Windows, Version 31.0 (IBM Corp., Armonk, NY, USA).

### RESULTS:

A total of 50 dry adult human atlas vertebrae were examined for the presence and morphological variations of the arcuate foramen. Arcuate foramen was identified in 12 specimens, yielding an overall incidence of 24%. The remaining 38 vertebrae (76%) showed no evidence of bony bridging over the vertebral artery groove. Based on morphology, complete arcuate foramina were observed in 5 specimens (10%), whereas incomplete arcuate foramina were found in 8 specimens (16%). Thus, the incomplete type was more frequently encountered than the complete type (Table 1). With regard to laterality, among the complete arcuate foramina, 2 specimens (4%) were present on the right side, 2 specimens (4%) on the left side, and 1 specimen (2%) showed bilateral occurrence (Table 2). Among the incomplete arcuate foramina, 3 specimens (6%) were observed on the right side, 3 specimens (6%) on the left side, and 2 specimens (4%) were bilateral (Table 3). Unilateral arcuate foramina were more common than bilateral forms.

Morphometric analysis was performed on the complete arcuate foramina using a digital vernier calliper. The mean anteroposterior diameter was  $9.13 \pm 1.05$  mm, ranging from 8.11 mm to 10.56 mm. The mean superoinferior diameter was  $8.01 \pm 0.98$  mm, with a range of 7.13 mm to 10.15 mm (Table 4). The findings of the present study indicate that the arcuate foramen is a relatively common anatomical variation of the atlas vertebra, with incomplete forms occurring more frequently than complete forms.

**Table 1. Frequency Distribution of Complete and Incomplete Arcuate Foramina in Atlas Vertebrae**

Type of Arcuate Foramen	Number (n)	Percentage (%)
Complete	05	10
Incomplete	08	16
Total	13	26

**Table 2. Laterality Pattern of Complete Arcuate Foramina Observed in Atlas Vertebrae**

Side	Number (n)	Percentage (%)
Right	02	04
Left	02	04
Bilateral	01	02
Total	05	10

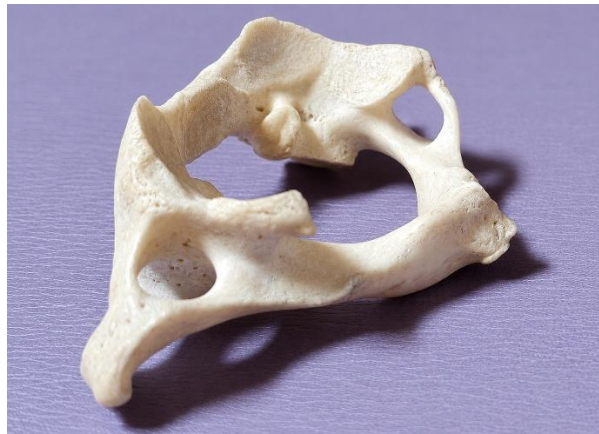**Table 3. Laterality Pattern of Incomplete Arcuate Foramina Observed in Atlas Vertebrae**

Side	Number (n)	Percentage (%)
Right	03	06
Left	03	06
Bilateral	02	04
Total	08	16

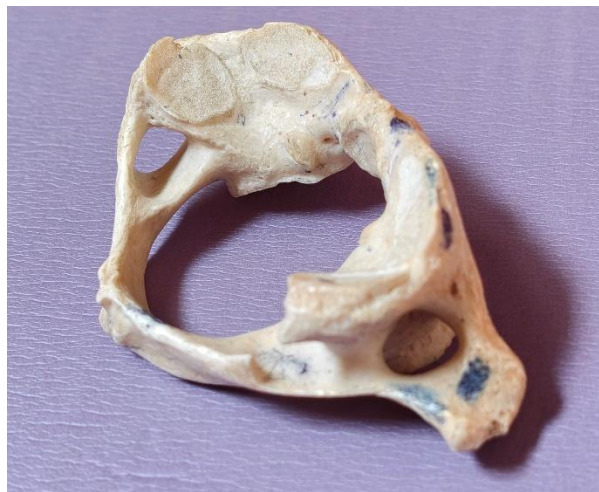**Table 4. Morphometric Characteristics of Complete Arcuate Foramina (in mm)**

Parameter	Mean $\pm$ SD (mm)	Range (mm)
-----------	--------------------	------------

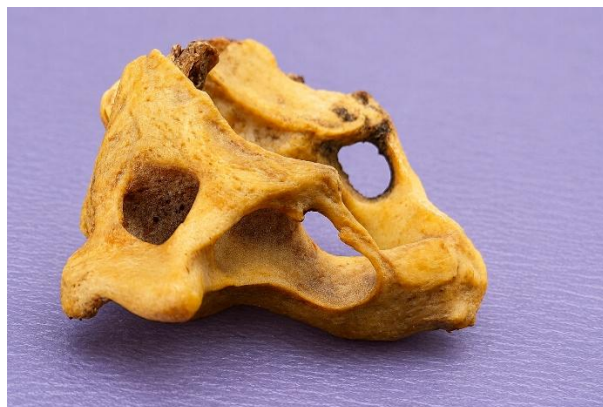Anteroposterior diameter (APD)	9.13 ± 1.05	8.11-10.56
Superoinferior diameter (SID)	8.01 ± 0.98	7.13-10.15



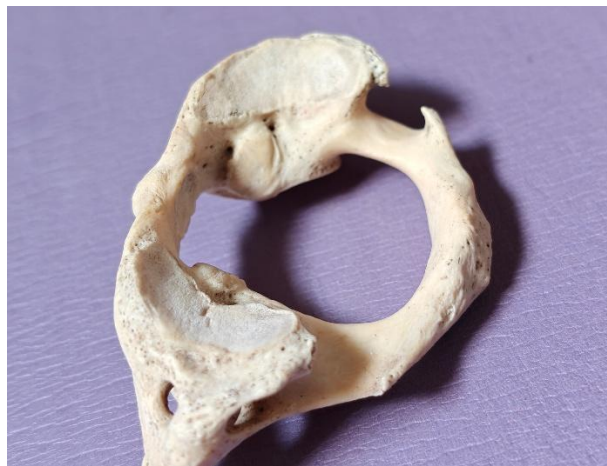
**Figure 1: Complete Arcuate Foramen on the Right Side of the Atlas Vertebra**



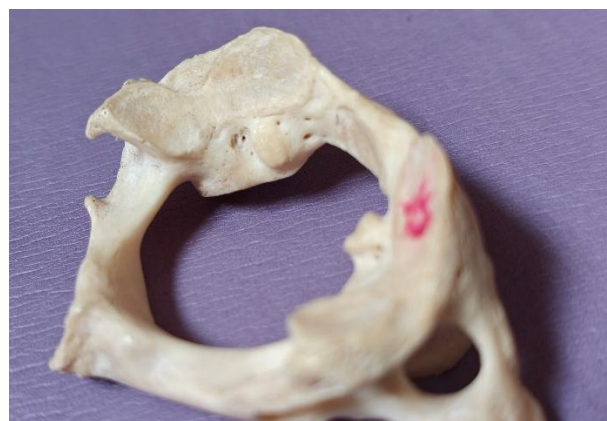**Figure 2: Complete Arcuate Foramen on the Left Side of the Atlas Vertebra**



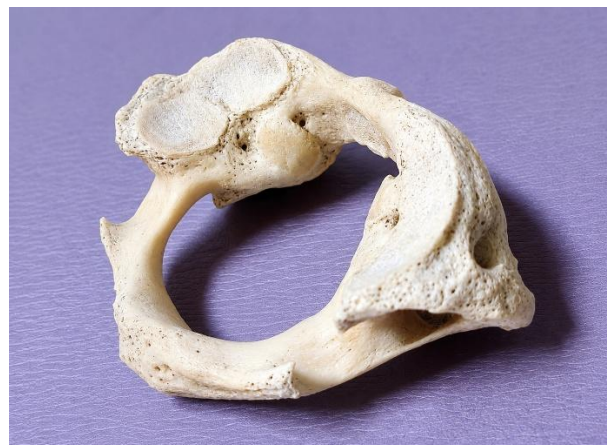**Figure 3: Bilateral Complete Arcuate Foramina of the Atlas Vertebra**



**Figure 4: Incomplete Arcuate Foramen on the Right Side of the Atlas Vertebra**



**Figure 5: Incomplete Arcuate Foramen on the Left Side of the Atlas Vertebra**



**Figure 6: Bilateral Incomplete Arcuate Foramina of the Atlas Vertebra**

#### **DISCUSSION:**

The arcuate foramen (ponticulus posticus) represents a common anatomical variation of the atlas vertebra, formed by ossification of the posterior atlanto-occipital membrane over the vertebral artery groove. The present study, conducted on 50 dry adult human atlas vertebrae from the Bihar population, revealed an overall incidence of 24%, with complete arcuate foramina in 10% and incomplete forms in 14% of specimens. Incomplete arcuate foramina were more common than complete forms, and unilateral presentation was more frequent than bilateral. Right-sided occurrence was noted in both complete and incomplete varieties, though left-sided and bilateral cases were also observed.

The prevalence of the arcuate foramen demonstrates substantial heterogeneity across different populations and geographical regions. The overall prevalence of 24% observed in the current investigation is broadly consistent with multiple earlier reports from India while showing noteworthy differences when compared to data from other parts of the world.

Investigations conducted within India have reported variable frequencies. A study by Akhtar et al. [11] on 118 atlas vertebrae from Bihar documented a 21.17% incidence of ponticulus posterior, with complete rings accounting for 7.62% and incomplete rings for 13.55% of specimens. Consistent with the present findings, they noted that the incomplete variety was more prevalent than the complete form, and right-sided occurrence was more frequent. Lalit et al. [12] examined a North Indian Punjabi population and found posterior bridges in 23.33% of cases, comprising 10% complete and 13.33% incomplete rings, figures that closely mirror the current results. In Central Gujarat, Vyas et al. [4] reported incomplete ponticulus posticus in 33% and complete forms in 4% of 100 atlas vertebrae, demonstrating a higher proportion of incomplete bridges but a lower proportion of complete bridges relative to the present study. Joshi et al. [13] documented ponticuli in 30% of 60 atlas vertebrae (6.66% complete, 23.33% incomplete), with bilateral involvement observed in 21.66% of cases. A South Indian study by Krishnamurthy et al. [14] reported an 8.33% incidence of complete arcuate foramen, which is marginally lower than the 10% figure obtained in the current work. Dahiphale and Bahetee [15] observed a complete ring in 2% and an incomplete ring in 18% of atlas vertebrae from Maharashtra, while Zambare and Reddy [16] reported a complete ring in 4% and an incomplete ring in 12% of specimens. This spectrum of regional variation within India suggests potential contributions from ethnic, genetic, or environmental determinants.

Beyond the Indian subcontinent, considerable variation in prevalence has also been documented. Mitchell [5] identified a 9.8% incidence of complete retroarticular canal in a South African population, whereas Karau et al. [17] reported 14.7% in a Kenyan cohort. Sanchis-Gimeno et al. [3] found a 13.3% prevalence of complete arcuate foramen in sub-Saharan African subjects, with inter-ethnic differences (Sotho 6.7%, Xhosa 23.3%, Zulu 10.0%). Among European populations, Cakmak et al. [18] noted an 8% prevalence in Turkish individuals, while Paraskevas et al. [19] reported a 34.66% incidence of posterior bridges (10.23% complete, 24.43% incomplete) in a Greek population. A comprehensive meta-analysis by Valenzuela-Fuenzalida et al. [20], incorporating 65 studies with 27,731 individuals, calculated an overall arcuate foramen prevalence of 16% (CI: 11%-20%) with substantial heterogeneity (98.8%) across included studies. This global diversity in prevalence likely arises from a combination of genetic predisposition, racial background, environmental exposures, and methodological differences in specimen collection and assessment. With respect to morphological classification, the distinction between complete and incomplete arcuate foramina carries clinical importance, as complete bony rings are more prone to causing significant vertebral artery compression. In the current series, incomplete forms (14%) outnumbered complete forms (10%), a pattern that aligns with observations by Akhtar et al. [11], Lalit et al. [12], and Hasan et al. [21]. Hasan et al. [21] proposed a six-tier classification scheme based on posterior arch morphology: Class I (impression of vertebral artery, 47.4%), Class II (distinct groove, 42.9%), Class III (partial posterior ponticulus, 3.14%), Class IV (complete posterior ponticulus, 3.42%), Class V (lateral bridge, 2.0%), and Class VI (posterolateral tunnel, 1.14%). The present findings reinforce the concept that most atlas vertebrae exhibit only impressions or grooves, with progressive ossification leading to partial and complete bridges in a minority of cases. Regarding laterality, the current investigation demonstrated a right-sided predominance for both complete (right 4% vs. left 4% with bilateral 2%) and incomplete (right 6% vs. left 6% with bilateral 4%) arcuate foramina. This observation contrasts with the work of Paraskevas et al. [19], who found a higher left-sided incidence (5.11% left vs. 2.84% right), and with Lalit et al. [12], who also reported left-sided predominance for complete rings (8.33% left vs. 5% right). Akhtar et al. [11] described a right-sided predominance for complete ponticulus posterior but bilateral predominance for the incomplete variety. These discrepancies may be explained by population-specific factors, including genetic drift, habitual postures, or asymmetrical muscle development. Dhall et al. [10] proposed that left-sided predominance observed in certain populations might result from unequal weight-bearing due to a commonly left-tilted head posture, whereas right-handed individuals may develop stronger right sternocleidomastoid muscles, tilting the head to the left. The present study demonstrated an equal distribution between the right and left sides, with unilateral variants being more common than bilateral forms.

Morphometric evaluation of complete arcuate foramina in the present study yielded a mean anteroposterior diameter of  $9.13 \pm 1.05$  mm (range: 8.11–10.56 mm) and a mean superoinferior diameter of  $8.01 \pm 0.98$  mm (range: 7.13–10.15 mm). These dimensions are comparable to those documented by Krishnamurthy et al. [14], who reported mean lengths of 9.99 mm on the right and 7.16 mm on the left in bilateral cases, with vertical heights of 6.52 mm (right) and 6.57 mm (left). Unur et al. [22] recorded a mean height of 5.7 mm (range: 3.7–8.5 mm) and a mean length of 8.1 mm (range: 5.7–10.0 mm). Tubbs et al. [2] reported a mean cross-sectional area of 14.2 mm<sup>2</sup> for the arcuate foramen. Variability in these measurements across different studies may relate to differences in measurement protocols, population characteristics, and sample sizes. The dimensions of the arcuate foramen are clinically relevant because a smaller foramen may predispose to greater compression of the vertebral artery, particularly during rotational neck movements.

The clinical significance of the arcuate foramen is fundamentally linked to its anatomical relationship with the vertebral artery, which traverses this bony canal together with the suboccipital nerve (dorsal ramus of C1) and the vertebral venous plexus. The presence of either a complete or an incomplete bony bridge can compress these neurovascular structures, potentially leading to vertebrobasilar insufficiency, especially during extreme rotation or lateral flexion of the head and neck.

A spectrum of symptoms has been associated with the arcuate foramen, including cervicogenic headache, migraine, vertigo, dizziness, visual disturbances, neck and shoulder pain, neurosensory hearing loss, and Barré-Liéou syndrome (characterised by retro-orbital pain, visual alterations, and vasomotor disturbances) [6,7]. In a cross-sectional study of 220

Italian patients using cone beam computed tomography, Macri et al. [6] identified a significant positive association between migraine and ponticulus posticus ( $p < 0.05$ ), with this variant being more frequent in migraine without aura (32.608%) compared to migraine with aura (19.565%). They concluded that CBCT evaluation of the ponticulus posticus might serve as a novel and valuable predictor for migraine diagnosis. Similarly, Sabir et al. [23] reported a positive association between this bony bridge and migraine, attributing the relationship to vertebral artery occlusion induced by the anomalous structure. Mechanical compression of the vertebral artery during head rotation may precipitate transient ischaemic episodes, and clinicians evaluating patients with unexplained cervicogenic symptoms should be aware of this anatomical variant.

The surgical implications of the arcuate foramen are particularly profound for procedures involving the craniovertebral junction, especially posterior C1 lateral mass screw fixation performed for atlantoaxial instability. As emphasised by Sonntag [24] and Arslan et al. [8], the presence of an arcuate foramen can create a false impression that the posterior arch of the atlas possesses adequate dimensions to accommodate lateral mass screws, potentially leading to inadvertent vertebral artery injury. The meta-analysis conducted by Elliott and Tanweer [7] stressed that preoperative recognition of the arcuate foramen is essential to avoid iatrogenic vertebral artery injury during the Goel-Harms procedure. Valenzuela-Fuenzalida et al. [20] similarly concluded that insufficient knowledge of arcuate foramen anatomy can result in complications such as vertebral artery injury and compromised blood flow to the brain, cerebellum, and brainstem. Furthermore, during foramen magnum decompression or occipitocervical fusion, the presence of this variant may alter the surgical approach and necessitate modifications to standard techniques to prevent neurovascular damage.

From a radiological perspective, the arcuate foramen is readily identifiable on plain lateral cervical radiographs; however, computed tomography (CT) and cone beam CT (CBCT) offer superior visualisation of laterality and completeness. Bayrakdar et al. [9] recommended cone beam CT for accurate detection. Given the relatively high prevalence of approximately 20–24% in many populations, including the one studied here, preoperative screening for the arcuate foramen should be considered in patients scheduled for craniovertebral surgery. Failure to detect this variation may lead to catastrophic complications, including vertebral artery laceration, pseudoaneurysm formation, or vertebrobasilar stroke.

#### Embryological and Phylogenetic explanation

The developmental origin of the arcuate foramen remains a subject of ongoing debate. Several hypotheses have been proposed to explain its formation: (1) congenital persistence of the superior oblique process observed in lower mammals; (2) ossification of the oblique ligament of the atlas induced by pulsations of the vertebral artery; (3) late ossification of the lateral fibres of the posterior atlanto-occipital membrane as an age-related phenomenon; (4) a regressive morphological phenomenon representing the gradual disappearance of a structure that is permanently present in lower vertebrates [25]; (5) genetic inheritance [26]; and (6) external mechanical factors, such as carrying heavy loads on the head [27].

The observation of incomplete bridges in children and young adults, as reported by Kendrick and Biggs [28] and Lamberty and Zivanovic [25], supports the hypothesis that incomplete rings may represent precursors of complete rings, with progressive ossification occurring over time. Paraskevas et al. [19] found that incomplete canals were more common in the 5–44 years age group, whereas complete canals predominated in the 45–90 years age group, further substantiating the progressive ossification hypothesis. From a phylogenetic standpoint, the arcuate foramen exists as a normal and permanent structure in many non-human primates and lower mammals, suggesting that its presence in humans represents an evolutionary remnant inherited from quadrupedal ancestors, in whom the bony bridge provided additional attachment sites for neck extensor muscles. The higher prevalence observed in some populations may reflect incomplete evolutionary regression of this feature. Embryologically, the posterior atlanto-occipital membrane derives from mesenchyme surrounding the developing vertebral artery. Ossification centres may appear within this membrane as early as the second decade of life, with progressive calcification continuing into middle age, thereby explaining the higher prevalence of complete foramina in older age groups.

A large-scale meta-analysis by Pekala et al. [29], encompassing 55,985 subjects, reported a pooled prevalence of the foramen arcuale of 10.2% for complete forms, with significant geographic variation. The complete arcuate foramen prevalence of 10% observed in the current investigation falls within the range reported in that meta-analysis and aligns closely with the pooled estimate. The meta-analysis by Valenzuela-Fuenzalida et al. [20] found that imaging studies reported significantly higher arcuate foramen prevalence than donor studies ( $P = 0.032$ ), and bilateral findings were more common than unilateral findings ( $P = 0.019$ ). These observations highlight the importance of methodological considerations in prevalence studies, as imaging techniques may detect subtle bony bridges that might be missed or over-interpreted in dry bone studies. The present dry bone investigation provides direct visualisation and accurate morphometric assessment, complementing the findings of radiological studies.

**Limitations of the Study:** The current study was conducted on dry human atlas vertebrae of unknown age and sex; consequently, age-related and sex-related variations could not be assessed. Furthermore, clinical and radiological correlations were beyond the scope of this investigation. The sample size of 50 vertebrae, while adequate for descriptive purposes, may limit the generalisability of the findings to the broader population. Nevertheless, the results provide

valuable baseline osteological data on the prevalence and morphology of the arcuate foramen in the studied Bihar population, which may serve as a reference for future clinical and radiological investigations in this region.

#### CONCLUSION:

The present osteological study demonstrates that the arcuate foramen is a relatively common anatomical variation of the atlas vertebra, observed in 24% of the examined specimens. Incomplete arcuate foramina were more frequent than complete forms, and unilateral variants predominated over bilateral occurrences. Morphometric evaluation of complete arcuate foramina provided baseline data regarding their anatomical dimensions. Given its close relationship with the vertebral artery and adjacent neurovascular structures, the arcuate foramen is of considerable clinical importance. Failure to recognise this variation during radiological evaluation or surgical procedures involving the craniovertebral junction may increase the risk of vertebral artery injury and related complications. Therefore, awareness of its presence and morphology is essential for anatomists, radiologists, neurosurgeons, and spine surgeons. The findings of the present study contribute valuable anatomical information and may aid in the safe planning of diagnostic and surgical interventions involving the upper cervical spine.

#### REFERENCES:

1. Standring S, Borley NR, Collins P, Crossman AR, Gatzoulis MA, Healy GC, et al. Gray's anatomy: the anatomical basis of clinical practice. 40th ed. London: Churchill Livingstone; 2008.
2. Tubbs RS, Johnson PC, Shoja MM, Loukas M, Oakes WJ. Foramen arcuale: anatomical study and review of the literature. *J Neurosurg Spine*. 2007;6(1):31-4.
3. Sanchis-Gimeno JA, Ercan I, Llido S, Toluk O, Cini NT, Ozdemir ST, et al. Arcuate foramen prevalence in South African subjects: a cadaveric study based on 120 atlas vertebrae. *Transl Res Anat*. 2023;33:100271.
4. Vyas K, Joshi HG, Patel S, Shroff B. Study of ponticulus posticus in dry atlas vertebrae in central Gujarat region and its clinical significance. *Int J Anat Radiol Surg*. 2017;6(4):38-41.
5. Mitchell J. The incidence and dimensions of the retroarticular canal of the atlas vertebra. *Acta Anat*. 1998;163:113-20.
6. Macri M, Rendina F, Feragalli B, Pegreff F, Festa F. Prevalence of ponticulus posticus and migraine in 220 orthodontic patients: a cross-sectional study. *Biology*. 2023;12:471.
7. Elliott RE, Tanweer O. The prevalence of the ponticulus posticus (arcuate foramen) and its importance in the Goel-Harms procedure: meta-analysis and review of the literature. *World Neurosurg*. 2014;82:e335-43.
8. Arslan D, Ozer MA, Govsa F, Kits O. The ponticulus posticus as risk factor for screw insertion into the first cervical lateral mass. *World Neurosurg*. 2018;113:e579-85.
9. Bayrakdar IS, Miloglu O, Altun O, Gumussoy I, Durna D, Yilmaz AB. Cone beam computed tomography imaging of ponticulus posticus: prevalence, characteristics, and a review of the literature. *Oral Surg Oral Med Oral Pathol Oral Radiol*. 2014;118:e210-9.
10. Dhall U, Chhabra S, Dhall JC. Bilateral asymmetry in bridges and superior articular facets of atlas vertebra. *J Anat Soc India*. 1993;42(1):23-7.
11. Akhtar MJ, Fatima N, Ritu, Kumar V. A morphological study of ponticuli of the human atlas vertebrae and its clinical significance. *Int J Anat Res*. 2015;3(4):1597-602.
12. Lalit M, Piplani S, Arora AK, Kullar JS, Sharma T. Incidence of atlas bridges and tunnels: their phylogeny, ontogeny and clinical implications. *Rev Arg de Anat Clin*. 2014;6(1):26-34.
13. Joshi MM, Pakhale S, Pawar K. A morphological study of ponticuli of the human atlas vertebrae. *Indian J Clin Anat Physiol*. 2025;12(2):58-62.
14. Krishnamurthy A, Nayak SR, Khan S, Prabhu L V, Ramanathan LA, Kumar CG, et al. Arcuate foramen of atlas: incidence, phylogenetic and clinical significance. *Rom J Morphol Embryol*. 2007;48(3):263-6.
15. Dahiphale VP, Bahetee BH. The retroarticular vertebral artery ring of the atlas and its significance. *J Anat Soc India*. 2009;58:149-51.
16. Zambare BR, Reddy BB. The retroarticular ring of the atlas and its clinical significance. *Anatomica Karnatka*. 2011;5(2):74-6.
17. Karau PB, Ogeng'o JA, Hassanali J, Odula PO. Morphometry and variations of bony ponticles of the atlas vertebrae (C1) in Kenyans. *Int J Morphol*. 2010;28(4):1019-24.
18. Cakmak O, Gurdal E, Ekinci G, Yildiz E, Cavdar S. Arcuate foramen and its clinical significance. *Saudi Med J*. 2005;26:1409-13.
19. Paraskevas G, Papaziogas B, Tsonidis C, Kapetanios G. Gross morphology of the bridges over the vertebral artery groove on the atlas. *Surg Radiol Anat*. 2005;27(2):129-36.
20. Valenzuela-Fuenzalida JJ, Cornejo-Peña J, Martinez-Cid J, Rojas-Acuña C, Granite G, Sanchis-Gimeno JA, et al. Arcuate foramen of the atlas vertebra and its correlation with clinical implications in the craniocervical region: a systematic review and meta-analysis. *World Neurosurg*. 2026;205:124652. doi:10.1016/j.wneu.2025.124652.
21. Hasan M, Shukla S, Siddiqui MS, Singh D. Posterolateral tunnels and ponticuli in human atlas vertebrae. *J Anat*. 2001;199:339-43.
22. Unur E, Erdogan N, Ulger H, Ekinci N, Ozturk O. Radiographic incidence of complete arcuate foramen in Turkish population. *Erciyes Med J*. 2004;26(2):50-4.
23. Sabir H, Kumbhare S, Rout P. Evaluation of ponticulus posticus on digital lateral cephalograms and cone beam

- computed tomography in patients with migraine and healthy individuals: a comparative study. *Oral Surg Oral Med Oral Pathol Oral Radiol.* 2014;118:348-54.
24. Sonntag VK. Beware of the arcuate foramen. *World Neurosurg.* 2014;82:e141-2.
  25. Lamberty BGH, Zivanovic S. The retro-articular vertebral artery ring of the atlas and its significance. *Acta Anat.* 1973;85:113-22.
  26. Selby S, Garn SM, Kanareff V. The incidence and familial nature of a bony bridge on the first cervical vertebra. *Am J Phys Anthropol.* 1955;13:129-41.
  27. Taitz C, Nathan H. Some observations on the posterior and lateral bridge of the atlas. *Acta Anat.* 1986;127:212-7.
  28. Kendrick GS, Biggs NL. Incidence of the ponticulus posticus of the first cervical vertebra between ages six to seventeen. *The Anatomical Record.* 1963 Mar;145(3):449-53.
  29. Pekala PA, Henry BM, Pekala JR, Hsieh WC, Vikse J, Sanna B, et al. Prevalence of foramen arcuate and its clinical significance: a meta-analysis of 55,985 subjects. *J Neurosurg Spine.* 2017;27:276-90.