



Original Article

DUODENAL PERFORATION IN LAKHIMPUR MEDICAL COLLEGE AND HOSPITAL - AN EPIDEMIOLOGICAL STUDY

Dr. Gautam Kamal¹, Dr. Devid Hazarika², Dr. Diganta Bora³, Dr. Debashri Bora⁴

¹ Assistant Professor, Department of Surgery, Lakhimpur Medical College and Hospital, Assam

² Associate Professor, Department of Surgery, Lakhimpur Medical College and Hospital, Assam

³ Associate Professor, Department of Anaesthesiology, Lakhimpur Medical College and Hospital, Assam

⁴ Assistant Professor, Department of Pharmacology, Lakhimpur Medical College and Hospital, Assam

OPEN ACCESS

ABSTRACT

Corresponding Author:

Dr. Debashri Bora

Assistant Professor, Department
of Pharmacology, Lakhimpur
Medical College and Hospital,
Assam.

Received: 15-04-2026

Accepted: 24-05-2026

Available online: 08-06-2026

Background: Duodenal perforation is one of the most common problem encountered in the emergency ward, requiring immediate surgical intervention. It is mostly due to peptic ulcer diseases, which is also a common complaint in today's world. Peptic ulcer disease may lead to duodenal or gastric perforation. Approximately, 5-10 percent of patient with duodenal ulcer may develop perforations. In our study, we will be evaluating the incidence of duodenal perforation among patients admitted in the department of Surgery, Lakhimpur Medical College and Hospital.

Aim: Our aim is to find out the prevalence of Duodenal perforation among patients admitted in the department of Surgery, Lakhimpur Medical College and Hospital.

Methods: After obtaining approval from institutional ethical committee, data was collected from medical records department of Surgery, Lakhimpur Medical College and Hospital. Data was collected from 1st Jan 2022 to 31st Dec 2025. Our study included 79 patients, presenting with hollow viscus perforation. Out of which, 57 patients were confirmed to have duodenal perforation. The demographic and socioeconomic profile of the patients were collected.

Results: Total 79 patients had undergone emergency exploratory laparotomy suspected of hollow viscus perforation. 57 (72.1%) number of patients were confirmed for duodenal perforation, 55 were males, 2 were females. The age distribution of patients were from (16 - 85) years in males and (15- 45) years in females. 57.8 % belongs to lower, 33.33% to middle and 8.77% to upper socio economic group.

Copyright © International Journal of
Medical and Pharmaceutical Research

Keywords: Duodenal perforation, Hollow viscus perforation, prevalence.

INTRODUCTION

Hollow viscus perforation, is the perforation of the gastrointestinal tract anywhere from the stomach, duodenum, jejunum, ileum to the small intestine and the large intestine. The breach in the wall causes leakage of alimentary contents, leading to contamination, infection and ultimately peritonitis.¹ Leakage of alimentary contents into the peritoneal cavity, is a common surgical emergency encountered in the emergency department. Perforation can be spontaneous or traumatic. Traumatic perforations can be due to foreign body ingestion of sharp objects or corrosive items or iatrogenic like during endoscopies. Peptic Ulcer disease (PUD) remains the main cause of spontaneous perforation. Other causes like malignant tumors, Crohn's disease, diverticulitis and appendicitis can also lead to rupture of bowel.^(2,3,4) The main etiology of PUD being *Helicobacter pylori* (H.Pylori) along with use of NSAIDs, alcohol abuse, smoking and environmental factors.^(5,6,7,8) It occurs due to an imbalance between mucosal defense mechanism and the damaging forces, particularly gastric acid and pepsin. Failure of mucosal defenses against gastric acid and pepsin results in ulceration.⁽⁹⁾ Peptic ulcer disease may lead to duodenal or gastric perforation. Approximately, 5-10% of patients with duodenal ulcer may develop perforations.⁽¹⁰⁾ Anterior duodenal ulcers perforate and posterior ulcer bleeds. Patients usually presents with acute abdomen with or without signs of peritonitis (sepsis). Plain picture abdomen (Xray in erect posture) may show signs of gas under diaphragm. USG might reveal intraperitoneal free air. Of all investigations, abdominal CT is the most sensitive and specific for identifying the exact cause of perforation.⁽¹¹⁾

Duodenal perforation is a rare but potentially life threatening condition. The mortality ranges from 8% to 25 %.^(12,13,14) Immediate surgery is required for patients presenting with peritonitis and or intra abdominal sepsis. Conservative management seems to be feasible in stable patients with sealed perforations.

Muralto and Lenepneau first described perforate duodenal ulcer in 1688.⁽¹⁵⁾ Dean reported the first successful surgical closure of a perforated duodenal ulcer in 1894.⁽¹⁶⁾

Aim of our study is to find out the prevalence of duodenal perforation among the patients admitted in the department of surgery, Lakhimpur Medical College and Hospital.

Objectives - the objective of our study is to evaluate the prevalence of duodenal perforation with respect to age, sex, economic status and clinical features, among the patients admitted in the department of surgery, Lakhimpur Medical College.

METHODOLOGY

After obtaining Institutional ethical clearance, data was collected from medical records department of Lakhimpur Medical College. The total number of patients admitted in the department of surgery from 1st Jan, 2022 to 31st Dec, 2025 was found to be 10552. Out of which 5078 were males and 5474 were females. Among those patients, a total of 79 patients were admitted with hollow viscus perforations with 71 were males and 8 females. The demographic profile of the patients were collected in respect to age, sex, indications and socio economic status.

RESULTS

In our study, a total of 10552 patients were admitted in the department of surgery, in the period of 4 years, viz 1st Jan, 2022 to 31st Dec, 2025. Total 79 patients had undergone emergency exploratory laparotomy suspected of hollow viscus perforation. 57(72.1%) number of patients were confirmed for duodenal perforation, 55 were males, 2 were females.

The age distribution of patients were from (16 - 85) years in males and (15- 45) years in females.

The most common complaint was pain abdomen followed by distension.

57.8 % belongs to lower, 33.33% to middle and 8.77% to upper socio economic group.

Table 1. Age distribution of patients undergoing emergency exploratory laparotomy for suspected hollow viscus perforation

Age Group (Years)	Male	Female	Total
< 20	6	2	8 (10.1%)
21 - 30	16	3	19 (24%)
31-40	16	2	18 (22.7%)
41-50	11	1	12 (15.1%)
51-60	10		10 (12.6%)
61-70	6		6 (7.9%)
71-80	4		4 (5%)
> 80	2		2 (2.5%)
	71 (89.8%)	8 (10.12%)	

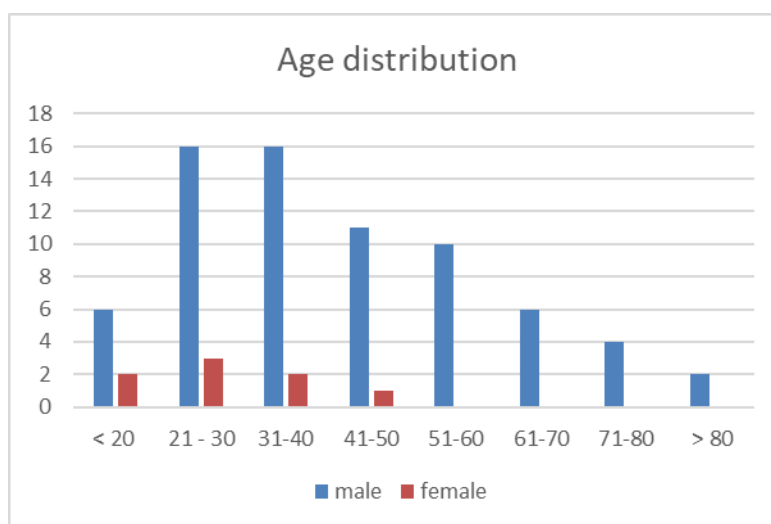


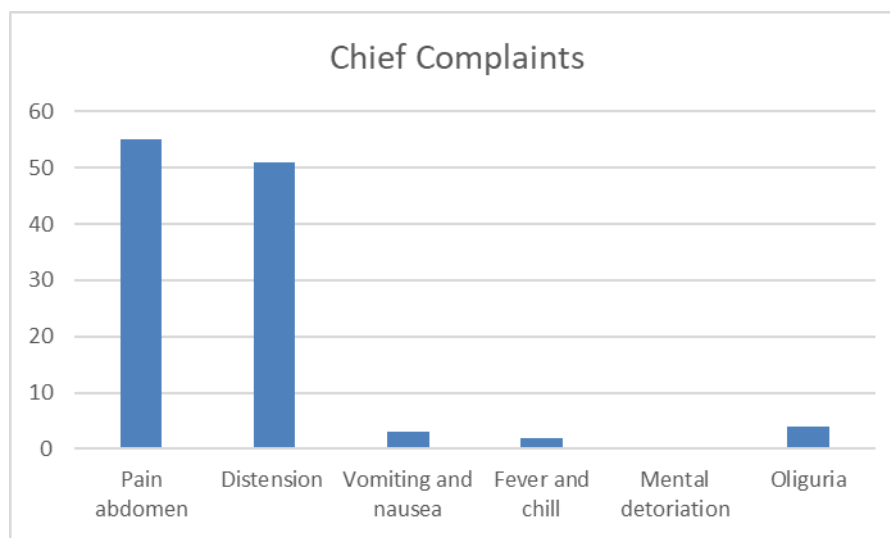
Figure 1

Table 2. Gender distribution of patients with Duodenal perforation

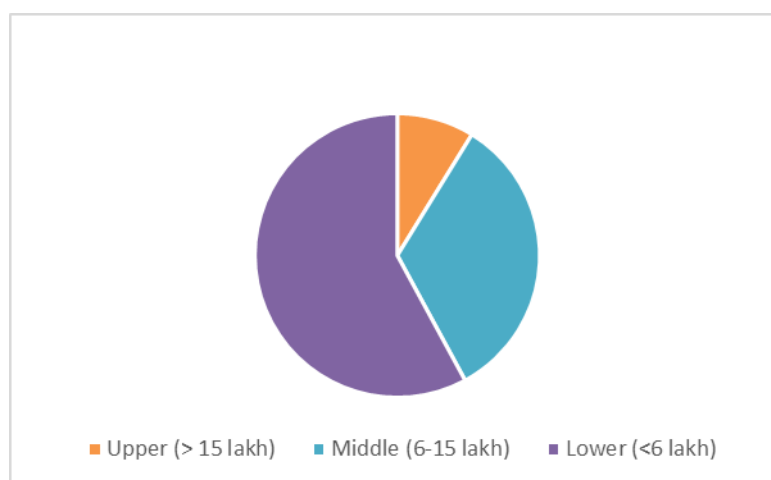
gender	numbers	%
Male	55	96.5
Female	2	3.5

Table 3. Chief complaints of patients with Duodenal Perforation

Pain abdomen	55	96.4%
Distension	51	89.4%
Vomiting and nausea	3	5.2%
Fever and chill	2	3.5%
Mental deterioration	0	0.0%
Oliguria	4	7%

**Figure 2.****Table 4. Socio economic distribution**

Gross family income		%
Upper (> 15 lakh)	5	8.77
Middle (6-15 lakh)	19	33.3
Lower (<6 lakh)	33	57.8

**Figure 3****Table 5. Type of perforation**

	Male	Female	%
Duodenal perforation	55	2	72.1
Gastric perforation	6	3	11.4

Traumatic	2		2.5
Appendicular	7	3	12.6
Tubercular	1		1.2
Malignant			

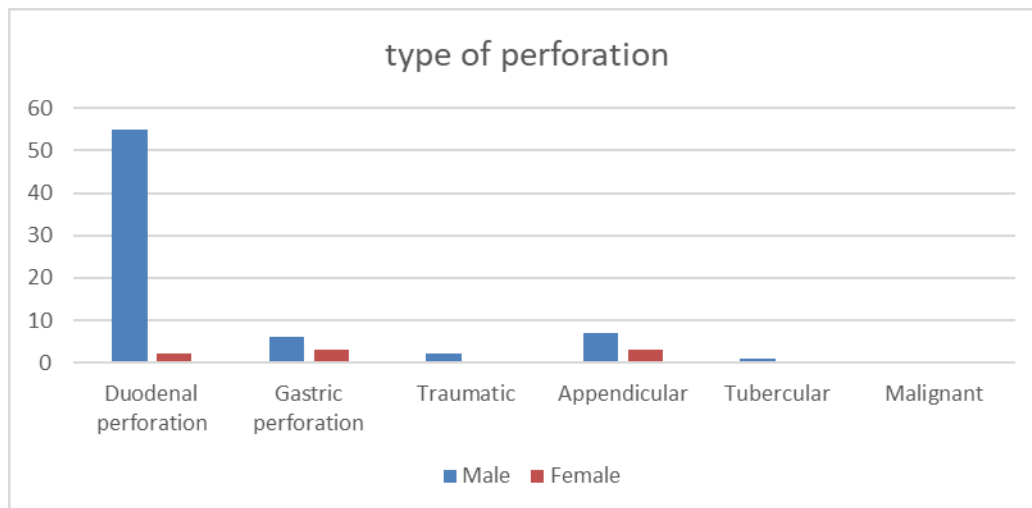


Figure 4.

DISCUSSIONS

In our study, we tried to evaluate 79 number of patients admitted for hollow viscus perforation. 57 (72.1%) number were found to have duodenal perforation after exploratory laparotomy. Males were more affected (96.5%) than females, and age group between 21-40 (37%) were predominantly affected. Other causes of perforation were appendicular (12.6%) and gastric perforation (11.4%).

Our findings are similar with Paul. H. Jordan, M.C.Danpat et al, Ramesh C et al,^(17,18,19) with duodenal perforation being common in males within 20-40 age group. Males with 96.5% and females with 3.5% were affected with duodenal ulcer. The minimum age recorded was 16 years and maximum was 85 years.

Out of 57 patients, 33 (57.8%) were from lower economic group. 19 (33.3%) from middle and 5 (8.77%) from upper economic group. Venkata Reddy M et al⁽²⁰⁾ also concluded that lower socioeconomic status had a higher prevalence of duodenal perforation due to higher incidence of smoking, alcohol and indiscriminate use of NSAIDs.

The most common complaints of the patients were pain abdomen (96.4%) followed by distention of abdomen (89.4%).

CONCLUSIONS

Hollow viscus perforation is one of the common acute abdominal emergencies encountered in surgical departments. And Duodenal perforation is the most common finding among them. Males have higher prevalence, may be due to unhealthy habits.

REFERENCES

1. Management of peritonitis in the critically ill patient. Ordonez C, Puyana J. Surg Clin North Am. 2006;86:1323-1349. doi:10.1016/j.suc.2006.09.006
2. Treatment of perforated diverticular disease of the colon. Hinchey EJ, Schaal PG, Richards GK. Adv Surg.1978;12:85-109
3. Appendicitis. Graffeo C, Counselman F. Emerg Med Clin N Am.1996;14:653-671.doi;10.1016/s0733-8627(05)70273
4. Practice parameters for sigmoid diverticulitis. Rafferty J, Shellito P, Hyman NH, Buie WD. Dis colon Rectum. 2006;89:939-944.doi:10.1007/s10350-006-0578-2.
5. Bertleff MJ, lanje JF. Perforated peptic ulcer disease: a review of history and treatment. Dig Sur. (2010) 27:161-9. 10.1159/000264653
6. Lau JY, Sung J, Hill C, Henderson C, Howden CW, Metz DC. Systematic review of the epidemiology of complicated peptic ulcer disease: incidence, recurrence, risk factors and mortality. Digestion. (2011) 84:102-13. 10.1159/000323958
7. Garcia Rodriguez LA, Barreales Tolosa L. Risk of upper gastrointestinal perforations among users of traditional NSAIDs and COXIBS in the general population. Gastroenterology. (2007) 132:498-506.10.1053/j.gastro.2006.12.007

8. Gisbert JP, Pajares JM. Helicobacter pylori infection and perforated peptic ulcer prevalence of the infection and role of antimicrobial treatment. *Helicobacter*. (2003) 8:159-67.10.1046/j.1523-5378.2003.00139.x
9. Shorrock CJ, Rees WDW. Overview of gastroduodenal mucosal protection. *The American journal of medicine*. 1988;84(2):25-84
10. Cheung LY, Declore R, Stomach In. Townsend CM, Beauchamp RD, Evers BM, Mattox KL; Sabiston Textbook of Surgery. Philadelphia: WB Saunders. 2001:8;37-860
11. Multidetector CT in emergency radiology: acute and generalised non traumatic abdominal pain. Paolantonio P, Rengo M, Ferrari R, Laghi A. *Br J Radiol*. 2016;89:20150859.doi:10.1259/bjr.20150859.
12. Machado NO. Management of duodenal perforation post endoscopic retrograde cholangiopancreatography. When and when to operate and what factors determine the outcome? A review article. *JOp*. 2012;13:18-25.
13. Moller MH, Adamsen S, Thomsen RW, et al. Multicentr trial of a perioperative protocol to reduce mortality in patients with peptic ulcer perforation. *Br J Surg*. 2011;98:802-810.
14. Lau JY, Sung J, Hill C, et al. Systemic review of the epidemiology of complicated peptic ulcer disease: incidence, recurrence, risk factors and mortality. *Digestion*. 2011;84:102-113.
15. Lenepneau I. Cas de perforation der duodenum de lien d'une ancienne cicatrice de cet intestina. *Gaz Hop*. 1839;35:137
16. Dean HP. A case of perforation of a chronic ulcer of the duodenum successfully treated by excision: deathe two months later from acute intestinal obstruction by a band. *Br Med J*. 1894;1:1014-1015
17. Paul JH, Jack T. Perforated pyloroduodenal ulcers. Long term results with omental patch closure and parietal cell vagotomy. *Ann Surg*. 1995;221-5:479-88
18. Dandapat MC, Mukherjee LM, Mishra B, Howlader PC. Gastrointestinal perforations, *Indian Journal of Surgery*. 1991;53(10):189-93
19. Ramesh C, Bharti et al: Immediate definitive surgery in perforated duodenal ulcer. A comparative study between definitive surgery and simple closure. *Indian journal of Surgery*. 1996;58(10):275-9
20. Venkata Reddy M, Sathish Kumar B, Suryanarayana Reddy V, Joopali Puneeth. Incidence of Duodenal Perforation in relation to the Socioeconomic status in a tertiary care hospital at Karimnagar. *Journal of Chalmeda Anand Rao Institute of Medical Sciences*. Vol 16, Issue 2, july-dec 2018.