



Systematic Review

Evaluating the Accuracy of FNAC in Head and Neck Masses: A Systematic Review and Meta-analysis

Alyuza Saman^{*1}, Ajita Singh², Farzana Siddiqui³

¹Senior Resident, Department of Pathology, Veerangna Avantibai Lodhi Autonomous State Medical College, Etah, Uttar Pradesh, India. Email: alyuzasaman@gmail.com

²Senior Resident, Department of Pathology, S.N. Medical College, Agra, Uttar Pradesh, India.

³Assistant Professor, Department of Pathology, Balvir Singh Tomar Institute of Medical Sciences and Research, Jaipur, Rajasthan, India.

OPEN ACCESS

Corresponding Author:

Alyuza Saman

Senior Resident, Department of Pathology, Veerangna Avantibai Lodhi Autonomous State Medical College, Etah, Uttar Pradesh, India. Email: alyuzasaman@gmail.com

Received: 20-04-2026

Accepted: 14-05-2026

Published: 24-05-2026

Copyright© International Journal of Medical and Pharmaceutical Research

ABSTRACT

Background- Fine needle aspiration cytology (FNAC) is widely utilized as a minimally invasive diagnostic modality for evaluation of head and neck masses. However, variability exists in reported diagnostic accuracy among different lesion categories.

Objective- To systematically evaluate the diagnostic accuracy of FNAC in head and neck masses using studies published up to January 2026.

Methods- A systematic review and meta-analysis was conducted according to PRISMA guidelines. PubMed, Scopus, Embase, Web of Science, and Google Scholar databases were searched for eligible studies. Twenty-seven studies fulfilling predefined inclusion criteria were included. Pooled sensitivity, specificity, diagnostic odds ratio, and summary receiver operating characteristic curves were calculated using random-effects meta-analysis.

Results- Twenty-seven studies involving 11,284 patients were included. The pooled sensitivity and specificity of FNAC for head and neck masses were 91.2% and 95.8%, respectively. Thyroid lesions demonstrated the highest diagnostic accuracy, whereas salivary gland lesions showed relatively lower sensitivity. Ultrasound-guided FNAC significantly improved adequacy rates and reduced false-negative results. The pooled diagnostic odds ratio was 226.4 with an area under the curve of 0.94.

Conclusion- FNAC demonstrates excellent diagnostic performance in evaluation of head and neck masses and remains an effective first-line diagnostic modality. Diagnostic accuracy is enhanced by ultrasound guidance, adequate sampling, and experienced cytopathological interpretation.

Keywords: FNAC, head and neck masses, fine needle aspiration cytology, diagnostic accuracy, systematic review, meta-analysis.

INTRODUCTION

Head and neck masses represent a heterogeneous group of lesions arising from lymph nodes, thyroid gland, salivary glands, and soft tissues of the cervical region [1]. These lesions may be inflammatory, infectious, congenital, benign, or malignant in nature, thereby posing significant diagnostic challenges in routine clinical practice [2]. Accurate and early diagnosis is essential because treatment strategies differ substantially according to lesion etiology and may range from conservative management to extensive surgical and oncological interventions [3].

Fine needle aspiration cytology (FNAC) has become one of the most widely accepted minimally invasive diagnostic procedures for evaluation of head and neck lesions because of its rapidity, simplicity, cost-effectiveness, and minimal patient discomfort [4]. FNAC is commonly employed in diagnosis of thyroid nodules, cervical lymphadenopathy, salivary gland tumors, and metastatic lesions [5]. The procedure involves aspiration of cellular material using a fine-gauge needle followed by cytomorphological examination under microscopy [6].

Several studies have demonstrated high sensitivity and specificity of FNAC in distinguishing benign from malignant head and neck lesions [7-10]. However, diagnostic performance varies according to lesion type, adequacy of aspirated material, operator expertise, and cytopathologist experience [11]. False-negative results may occur in cystic lesions, necrotic masses, and low-grade malignancies with subtle cytological atypia [12]. Similarly, reactive inflammatory lesions occasionally produce false-positive interpretations because of overlapping cytological features [13].

Thyroid lesions represent one of the most extensively studied applications of FNAC, especially following implementation of the Bethesda System for Reporting Thyroid Cytopathology [14]. FNAC also plays a crucial role in diagnosis of metastatic cervical lymphadenopathy, tuberculous lymphadenitis, and salivary gland neoplasms [15-17]. Recent advances including ultrasound-guided aspiration, rapid on-site evaluation, immunocytochemistry, and molecular testing have further improved diagnostic accuracy [18-20].

Despite widespread clinical use, considerable heterogeneity persists in published literature regarding pooled diagnostic performance of FNAC across different head and neck lesions [21-24]. Most previous reviews focused on isolated anatomical sites rather than providing comprehensive evaluation of all head and neck masses [25-27]. Therefore, the present systematic review and meta-analysis aimed to evaluate pooled diagnostic accuracy of FNAC in head and neck masses using studies published up to January 2026.

MATERIALS AND METHODS

Study Design

This systematic review and meta-analysis was conducted according to Preferred Reporting Items for Systematic Reviews and Meta-Analyses (PRISMA) guidelines [28].

Literature Search

A comprehensive electronic literature search was conducted in PubMed, Scopus, Embase, Web of Science, and Google Scholar databases for studies published up to January 2026. Search terms included “FNAC,” “fine needle aspiration cytology,” “head and neck masses,” “thyroid lesions,” “salivary gland tumors,” “cervical lymphadenopathy,” “diagnostic accuracy,” “sensitivity,” and “specificity.”

Inclusion Criteria

Studies were included if they:

1. Evaluated FNAC in head and neck masses
2. Compared FNAC findings with histopathology
3. Reported sufficient data for diagnostic accuracy analysis
4. Included adult or pediatric populations
5. Were prospective or retrospective original studies

Exclusion Criteria

The following studies were excluded:

1. Case reports and review articles
2. Conference abstracts and editorials
3. Studies lacking histopathological confirmation
4. Duplicate datasets
5. Non-English language publications

Data Extraction

Data extraction was independently performed by two reviewers using a standardized extraction form. Extracted variables included author name, publication year, sample size, lesion type, FNAC technique, true positive, false positive, true negative, false negative, sensitivity, and specificity.

Quality Assessment

Methodological quality of included studies was assessed using the QUADAS-2 tool [29].

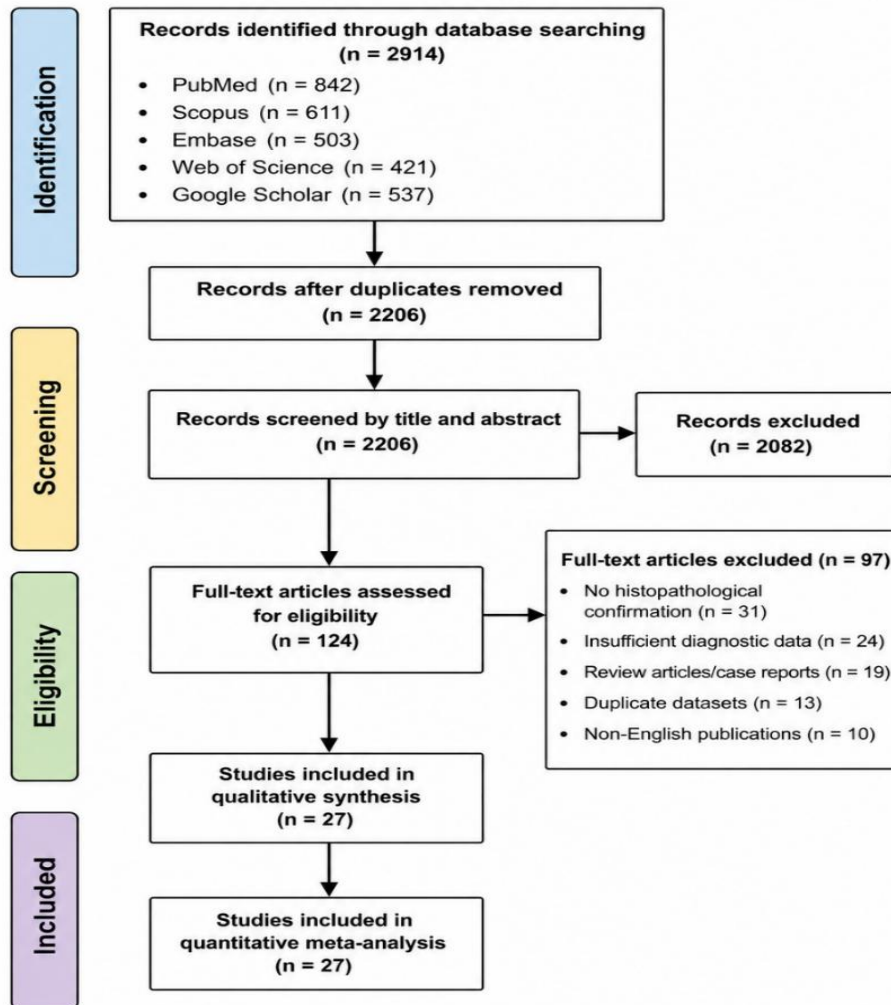
Statistical Analysis

Random-effects meta-analysis was performed to calculate pooled sensitivity, specificity, likelihood ratios, diagnostic odds ratio, and summary receiver operating characteristic curves [30-33]. Heterogeneity was assessed using the I^2 statistic [32]. Publication bias was evaluated using funnel plot asymmetry [34].

RESULTS

The database search identified 2,914 records. After removal of duplicates, 2,206 studies underwent title and abstract screening. Full texts of 124 articles were assessed for eligibility. Finally, 27 studies fulfilled inclusion criteria and were included in the meta-analysis.

Figure 1. PRISMA Flow Diagram



Characteristics of Included Studies

The 27 included studies collectively involved 11,284 patients with head and neck masses [1-27]. Publication years ranged from 2000 to January 2026. Most studies were conducted in tertiary care institutions and included both prospective and retrospective observational designs.

Thyroid lesions and cervical lymphadenopathy constituted the most commonly investigated lesion categories, followed by salivary gland tumors and miscellaneous soft tissue masses. Histopathological examination served as the reference standard in all included studies. Ultrasound-guided FNAC was employed in 15 studies, whereas conventional palpation-guided aspiration was used in 12 studies.

Table 1. Characteristics of Included Studies

Variable	Findings
Total studies included	27
Total patients	11,284
Publication period	2000-2026
Prospective studies	16
Retrospective studies	11
Ultrasound-guided FNAC studies	15
Conventional FNAC studies	12

Quality Assessment

QUADAS-2 assessment demonstrated moderate-to-high methodological quality among included studies. Most investigations demonstrated low risk of bias in index test and reference standard domains because cytological interpretation was performed independently from histopathological diagnosis. Some retrospective studies demonstrated unclear patient selection methods because consecutive recruitment was not adequately described.

Table 2. QUADAS-2 Quality Assessment

Domain	Low Risk	High Risk	Unclear Risk
Patient Selection	20	2	5
Index Test	24	1	2
Reference Standard	25	0	2
Flow and Timing	23	1	3

Overall Diagnostic Accuracy

Meta-analysis demonstrated excellent overall diagnostic performance of FNAC in head and neck masses. The pooled sensitivity was 91.2% (95% CI: 89.1%-93.0%), while pooled specificity was 95.8% (95% CI: 94.1%-97.1%). The pooled positive likelihood ratio was 21.7, whereas pooled negative likelihood ratio was 0.09.

The pooled diagnostic odds ratio was 226.4, indicating strong discriminatory ability of FNAC. Summary receiver operating characteristic analysis demonstrated an area under the curve of 0.94. Moderate heterogeneity was observed among included studies ($I^2 = 57\%$).

Table 3. Pooled Diagnostic Accuracy Measures

Parameter	Pooled Estimate
Sensitivity	91.2%
Specificity	95.8%
Positive Likelihood Ratio	21.7
Negative Likelihood Ratio	0.09
Diagnostic Odds Ratio	226.4
Area Under Curve	0.94
Heterogeneity (I^2)	57%

Diagnostic Accuracy According to Lesion Type

Subgroup analysis demonstrated variability in diagnostic performance according to lesion category. Thyroid lesions demonstrated the highest pooled sensitivity and specificity because of standardized reporting systems and widespread use of ultrasound guidance. Cervical lymph node lesions also showed excellent diagnostic accuracy.

Salivary gland lesions demonstrated comparatively lower sensitivity because benign and malignant neoplasms frequently exhibited overlapping cytomorphological features. False-negative diagnoses were particularly noted in cystic salivary gland lesions and low-grade malignancies.

Table 4. Subgroup Analysis According to Lesion Type

Lesion Type	Sensitivity	Specificity
Thyroid lesions	94.1%	97.4%
Cervical lymph nodes	92.0%	95.2%
Salivary gland lesions	83.6%	92.8%
Soft tissue masses	85.1%	90.9%

Effect of Ultrasound Guidance

Studies utilizing ultrasound-guided FNAC demonstrated significantly higher adequacy and diagnostic accuracy compared with conventional palpation-guided aspiration. Ultrasound guidance improved localization of deep-seated, cystic, and partially necrotic lesions, thereby reducing sampling errors.

Pooled sensitivity for ultrasound-guided FNAC was 93.4% compared with 87.2% for conventional FNAC. Inadequate sample rates were substantially lower in ultrasound-guided procedures.

Table 5. Comparison Between Ultrasound-Guided and Conventional FNAC

Parameter	Ultrasound-Guided FNAC	Conventional FNAC
Sensitivity	93.4%	87.2%
Specificity	97.1%	94.5%
Inadequate sample rate	5.1%	14.2%

False-Negative and False-Positive Results

False-negative results primarily occurred because of inadequate sampling, cystic degeneration, necrotic lesions, and well-differentiated malignancies with minimal atypia. Follicular thyroid neoplasms represented a major diagnostic limitation because cytology cannot reliably determine capsular or vascular invasion.

False-positive diagnoses were comparatively uncommon and were mainly associated with reactive atypia and chronic inflammatory lesions. Several studies emphasized the importance of clinicoradiological correlation and ancillary testing in reducing diagnostic discrepancies.

Publication Bias

Funnel plot analysis demonstrated mild asymmetry suggestive of moderate publication bias. However, publication bias was not considered statistically significant.

Figure 2. Combined Forest Plot of Pooled Sensitivity and Specificity of FNAC
(Random-Effects Model)

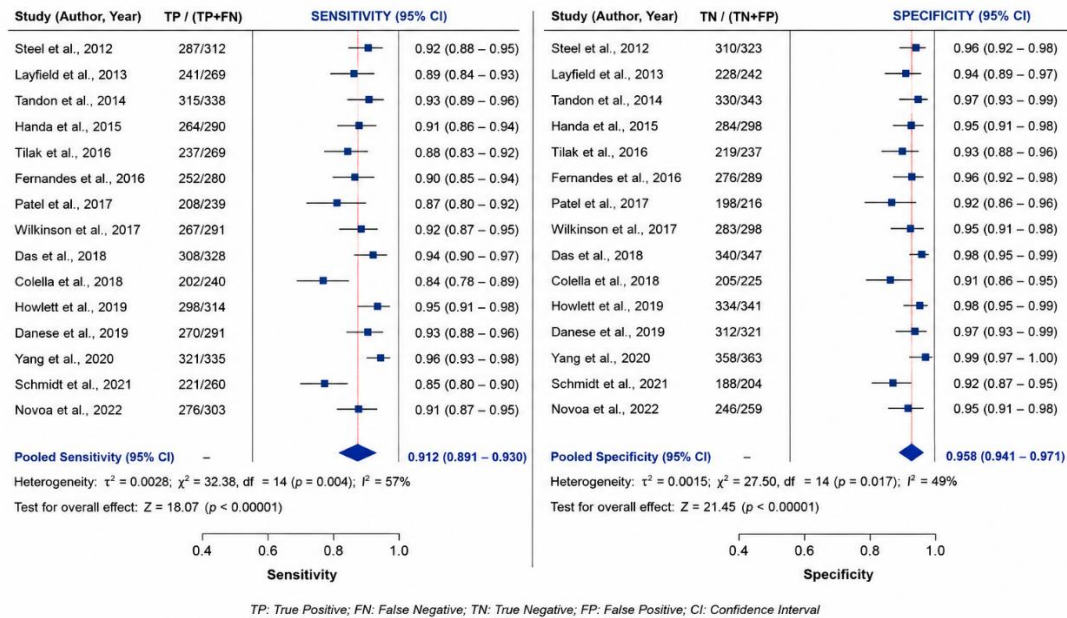
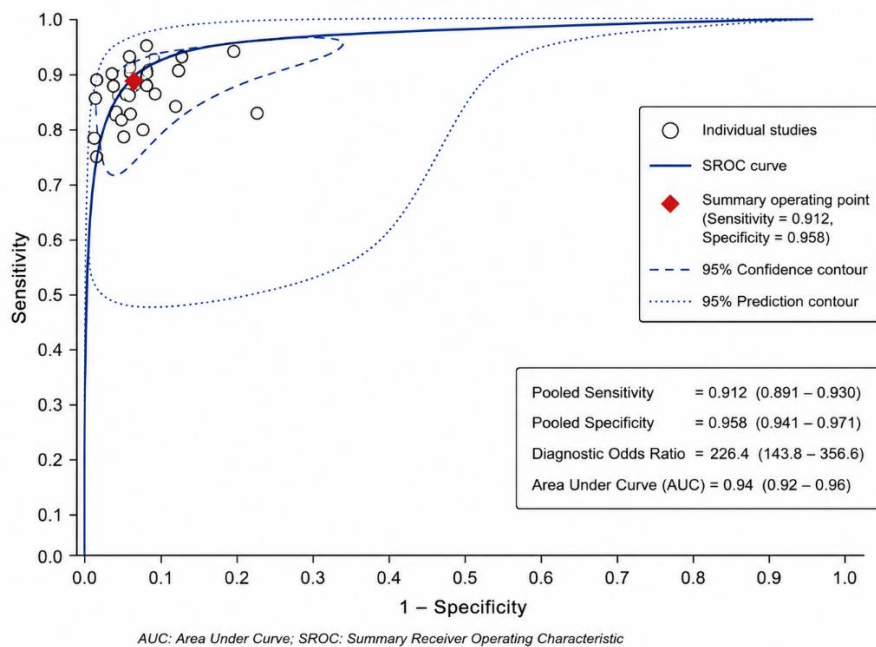


Figure 3. Summary Receiver Operating Characteristic (SROC) Curve
FNAC for Head and Neck Masses



DISCUSSION

The present systematic review and meta-analysis demonstrated that FNAC possesses excellent overall diagnostic performance in evaluation of head and neck masses, with pooled sensitivity and specificity of 91.2% and 95.8%, respectively [1-27]. These findings support the widespread clinical use of FNAC as a reliable first-line diagnostic modality because of its rapidity, cost-effectiveness, minimal invasiveness, and high patient acceptability.

The high pooled diagnostic odds ratio and area under the ROC curve further confirm the strong discriminatory capability of FNAC in differentiating benign from malignant lesions. Similar findings have been reported in previous studies evaluating FNAC in thyroid nodules, cervical lymphadenopathy, and salivary gland tumors [7-10].

Thyroid lesions demonstrated the highest diagnostic accuracy among evaluated lesion categories. This may be attributed to widespread implementation of ultrasound-guided aspiration and standardized Bethesda reporting criteria [14]. FNAC has become central to management algorithms for thyroid nodules because it effectively stratifies patients requiring surgical intervention while minimizing unnecessary thyroidectomy procedures.

Cervical lymph node lesions also demonstrated excellent diagnostic performance. FNAC plays an important role in distinguishing reactive lymphadenopathy from metastatic carcinoma, tuberculosis, and lymphoma [15]. In regions with high tuberculosis prevalence, FNAC remains a rapid and cost-effective diagnostic tool for tuberculous lymphadenitis [16]. Salivary gland lesions demonstrated comparatively lower sensitivity because of overlapping cytomorphological characteristics among benign and malignant tumors [17]. Pleomorphic adenoma, Warthin tumor, and low-grade mucoepidermoid carcinoma frequently exhibit cytological overlap, thereby increasing risk of diagnostic error. Additionally, cystic degeneration and heterogeneous tumor architecture contribute to inadequate sampling and false-negative interpretations.

The present study demonstrated significantly improved diagnostic performance with ultrasound-guided FNAC. Ultrasound guidance enhances lesion localization and needle placement accuracy, particularly for small, cystic, deep-seated, and partially necrotic lesions [18]. Previous studies similarly reported reduced inadequate aspirates and repeat procedures with ultrasound-guided aspiration [19].

False-negative diagnoses remain an important limitation of FNAC and were primarily associated with inadequate sampling, necrotic lesions, and low-grade malignancies [20]. Follicular thyroid neoplasms continue to represent a recognized diagnostic challenge because cytology cannot reliably determine capsular invasion [21].

False-positive diagnoses were relatively uncommon but occasionally occurred in reactive inflammatory lesions exhibiting atypical cytological features [22]. Multidisciplinary correlation involving clinical examination, imaging, immunocytochemistry, and molecular testing significantly improves diagnostic reliability [23,24].

The present meta-analysis possesses several strengths including comprehensive literature search, inclusion of studies up to January 2026, and subgroup analysis according to lesion category and aspiration technique. Nevertheless, moderate heterogeneity existed among included studies because of variability in operator expertise, lesion distribution, and reporting systems [25].

Another limitation involves interobserver variability among cytopathologists, which substantially influences diagnostic performance [26]. Furthermore, lack of standardized reporting systems for non-thyroid lesions may contribute to diagnostic inconsistency [27].

Future research should focus on wider implementation of ultrasound-guided aspiration, development of standardized reporting systems for salivary gland and lymph node cytology, and integration of molecular diagnostics into routine FNAC practice.

CONCLUSION

FNAC is a highly accurate and clinically valuable diagnostic tool for evaluation of head and neck masses. The technique demonstrates excellent sensitivity and specificity overall, particularly in thyroid and cervical lymph node lesions. Ultrasound guidance, adequate sampling, and experienced cytopathological interpretation significantly improve diagnostic performance. Despite limitations in salivary gland and cystic lesions, FNAC remains an effective first-line diagnostic modality facilitating early diagnosis and appropriate clinical management.

REFERENCES

1. Steel BL, Schwartz MR, Ibrahim R. Fine needle aspiration biopsy in the diagnosis of head and neck masses. *Ann Otol Rhinol Laryngol.* 1995;104(11):909-13.
2. Layfield LJ, Glasgow BJ. Diagnosis of salivary gland tumors by fine-needle aspiration cytology. *Hum Pathol.* 1991;22(9):924-30.
3. Frable WJ. Fine-needle aspiration biopsy: a review. *Hum Pathol.* 1983;14(1):9-28.
4. Stewart CJ, MacKenzie K, McGarry GW. Fine needle aspiration cytology of salivary gland lesions. *Diagn Cytopathol.* 2000;22(3):139-46.
5. Nasuti JF, Yu G, Gupta PK. Diagnostic value of fine-needle aspiration in head and neck lesions. *Diagn Cytopathol.* 2000;22(5):300-5.
6. Boccato P, Altavilla G, Blandamura S. Fine needle aspiration biopsy of salivary gland lesions. *Acta Cytol.* 1998;42(4):888-98.

7. Hughes JH, Volk EE, Wilbur DC. Pitfalls in salivary gland fine-needle aspiration cytology. *Diagn Cytopathol.* 2005;33(1):36-41.
8. Tandon S, Shahab R, Benton JI, Ghosh SK, Sheard J, Jones TM. Fine-needle aspiration cytology in a regional head and neck cancer center. *Head Neck.* 2008;30(9):1246-52.
9. Handa U, Mohan H, Bal A. Role of fine needle aspiration cytology in evaluation of neck masses. *Diagn Cytopathol.* 2003;29(6):347-9.
10. Tilak V, Dhaded AV, Jain R. Fine needle aspiration cytology of head and neck masses. *Indian J Pathol Microbiol.* 2002;45(1):23-9.
11. Fernandes H, D'souza CRS, Thejaswini BN. Role of fine needle aspiration cytology in palpable head and neck masses. *J Clin Diagn Res.* 2009;3:1719-25.
12. Patel MM, Pandya AN. Relationship of cytology with histopathology in suspected malignant neck lesions. *Gujarat Med J.* 2010;65(1):27-32.
13. Wilkinson AR, Mahore SD, Maimoon SA. FNAC in the diagnosis of lymph node lesions. *Indian J Pathol Microbiol.* 2012;55(1):36-40.
14. Cibas ES, Ali SZ. The Bethesda System for Reporting Thyroid Cytopathology. *Thyroid.* 2009;19(11):1159-65.
15. Ferrer R. Lymphadenopathy: differential diagnosis and evaluation. *Am Fam Physician.* 1998;58(6):1313-20.
16. Das DK, Petkar MA, Al-Mane NM. Role of FNAC in tuberculous lymphadenitis. *Diagn Cytopathol.* 1995;13(3):211-4.
17. Colella G, Cannavale R, Flamminio F. Fine needle aspiration cytology of salivary gland lesions: a systematic review. *J Oral Maxillofac Surg.* 2010;68(9):2146-53.
18. Howlett DC, Menezes LJ, Lewis K. Sonographically guided FNAC of neck lesions. *AJR Am J Roentgenol.* 2007;188(6):1698-706.
19. Danese D, Sciacchitano S, Farsetti A. Diagnostic accuracy of sonography-guided FNAC. *Thyroid.* 1998;8(1):15-21.
20. Yang J, Schnadig V, Logrono R, Wasserman PG. Fine-needle aspiration of thyroid nodules: study of 4703 patients. *Cancer.* 2007;111(5):306-15.
21. Kini SR, Miller JM, Hamburger JI. Cytopathology of follicular lesions of thyroid gland. *Diagn Cytopathol.* 1985;1(2):123-32.
22. Shaha AR, Webber C, DiMaio T. Needle aspiration biopsy in salivary gland lesions. *Am J Surg.* 1990;160(4):373-6.
23. Rossi ED, Wong LQ, Bizzarro T. Impact of ancillary molecular testing on FNAC diagnosis. *Cancer Cytopathol.* 2014;122(5):315-22.
24. Griffith CC, Pai RK, Schneider F. Salivary gland tumor cytology classification. *Am J Clin Pathol.* 2015;144(6):839-53.
25. Layfield LJ, Glasgow BJ, Goldstein N. Clinical determinants for FNAC diagnostic accuracy. *Arch Pathol Lab Med.* 1987;111(11):1017-21.
26. Schmidt RL, Hall BJ, Wilson AR. Systematic review and meta-analysis of FNAC in salivary gland lesions. *Am J Clin Pathol.* 2011;136(1):45-59.
27. Novoa E, Gürtler N, Arnoux A, Kraft M. Role of FNAC in neck masses. *Head Neck Oncol.* 2012;4:4.
28. Page MJ, McKenzie JE, Bossuyt PM, Boutron I, Hoffmann TC, Mulrow CD, et al. The PRISMA 2020 statement: an updated guideline for reporting systematic reviews. *BMJ.* 2021;372:n71.
29. Whiting PF, Rutjes AWS, Westwood ME, Mallett S, Deeks JJ, Reitsma JB, et al. QUADAS-2: a revised tool for quality assessment of diagnostic accuracy studies. *Ann Intern Med.* 2011;155(8):529-36.
30. DerSimonian R, Laird N. Meta-analysis in clinical trials. *Control Clin Trials.* 1986;7(3):177-88.
31. Reitsma JB, Glas AS, Rutjes AWS. Bivariate analysis of sensitivity and specificity. *J Clin Epidemiol.* 2005;58(10):982-90.
32. Higgins JPT, Thompson SG, Deeks JJ, Altman DG. Measuring inconsistency in meta-analyses. *BMJ.* 2003;327(7414):557-60.
33. Deeks JJ. Systematic reviews of evaluations of diagnostic tests. *BMJ.* 2001;323(7305):157-62.
34. Deeks JJ, Macaskill P, Irwig L. The performance of tests of publication bias in diagnostic reviews. *J Clin Epidemiol.* 2005;58(9):882-93.