



Original Article

## Clinico-radiological Profile and Surgical Outcomes in Patients with Spinal Tuberculosis: A Prospective Observational Study

Dr Rahul Kumar<sup>1</sup>, Dr Abhinav Kumar Singh<sup>2</sup>, Dr Neha Rani<sup>3</sup>

<sup>1</sup>Associate Professor Department of Neurosurgery, ESIC Medical College & Hospital, Faridabad, Haryana, India,

<sup>2</sup>Senior Resident Department of Neurosurgery, ESIC Medical College & Hospital, Faridabad, Haryana, India,

<sup>3</sup>Assistant Professor Department of Anesthesia ESIC Medical College & Hospital, Faridabad, Haryana, India

 OPEN ACCESS

### Corresponding Author:

**Dr. Rahul Kumar**

Associate Professor Department of Neurosurgery, ESIC Medical College & Hospital, Faridabad, Haryana, India

Received: 15-10-2025

Accepted: 05-11-2025

Available online: 31-12-2025

Copyright© International Journal of Medical and Pharmaceutical Research

### ABSTRACT

**Context:** Spinal tuberculosis (TB) remains the most common form of skeletal tuberculosis and is associated with significant morbidity due to pain, neurological deficits, spinal instability, and deformity. Despite advances in diagnosis and treatment, delayed presentation and progressive neurological compromise remain common in endemic regions. Surgical intervention is indicated in selected patients with instability, deformity, neurological deficits, or failure of medical therapy. **Aims:** This study aims to evaluate the clinico-radiological profile and surgical outcomes of patients with spinal tuberculosis at a tertiary care center. **Settings and Design:** Prospective, observational, single-center study. **Methods and Materials:** 30 patients diagnosed with spinal tuberculosis requiring surgical intervention were recruited from the Department of Neurosurgery, ESIC Medical College, Faridabad, between 2024 and 2025. Baseline demographic, clinical, neurological, and radiological characteristics were recorded. Neurological status was assessed using Frankel grading, while pain was evaluated using Denis pain scale. Patients were followed postoperatively and reassessed clinically at regular intervals up to 3 months. **Statistical Analysis Used:** Data were analyzed using IBM SPSS Statistics; a p-value < 0.05 was considered significant. **Results:** The mean age was 35.53 years, with the dorsal spine (56.7%) being the most common site. Severe neurological deficits (Frankel A-C) presented significantly earlier than mild ones (p=0.0010). Significant neurological improvement was observed post-surgery, with 66.7% of patients reaching Frankel grade E at 3 months. Baseline neurological status was the only independent predictor of absolute recovery (p=0.0008). **Conclusions:** Surgical decompression and stabilization lead to significant neurological improvement and pain relief in spinal TB. Early intervention is critical, particularly as severe deficits tend to progress rapidly.

**Keywords:** Spinal tuberculosis; Pott disease; Frankel grade; Surgery; Outcome.

### INTRODUCTION

Spinal tuberculosis (TB) is the most common form of skeletal tuberculosis and remains a leading cause of non-traumatic spinal cord compression in endemic regions. Despite advances in diagnosis and chemotherapy, delayed presentation is common, often resulting in vertebral destruction, deformity, and neurological deficits [1–3].

The disease typically involves the anterior vertebral column due to hematogenous spread, leading to collapse, kyphosis, and formation of paravertebral or epidural abscesses. Neurological impairment arises from mechanical compression, instability, and vascular compromise of the spinal cord [4–6].

While anti-tubercular therapy is the cornerstone of management, surgical intervention is indicated in patients with progressive neurological deficit, spinal instability, deformity, or failure of medical therapy. Advances in spinal instrumentation have improved outcomes by enabling effective decompression and stabilization [2,7].

Neurological recovery following surgery is variable and depends on factors such as baseline neurological status, duration of symptoms, and extent of disease. Among these, preoperative neurological grade has been identified as a key predictor of outcome [8–10].

However, prospective data evaluating the pattern of neurological recovery and its determinants remain limited. The present study aims to assess neurological outcomes and identify predictors of recovery in surgically managed spinal TB patients.

## **MATERIALS AND METHODS**

### **Study Design**

Prospective observational study.

### **Sample Size**

30 patients.

### **Inclusion Criteria**

- Clinico-radiological diagnosis of spinal tuberculosis
- Indications for surgery:
  - Neurological deficit
  - Instability
  - Deformity
  - Failure of medical management

### **Exclusion Criteria**

- Non-tubercular infections
- Conservatively managed patients

### **Parameters Assessed**

- Demographics
- Symptom duration
- Level of involvement
- Neurological status (Frankel grade)
- Pain (Denis pain scale)
- Radiological findings

### **Follow-Up**

- Post-op Day 1
- 1 month
- 3 months

### **Statistical Analysis**

- Neurological improvement assessed
- Correlation analysis performed
- $p < 0.05$  considered significant

## **RESULTS**

### **Baseline Characteristics**

A total of 30 patients were included. The mean age was  $34.2 \pm 12.1$  years, with male predominance (19/30, 63.3%). The thoracic spine was most commonly involved (18/30, 60%), followed by lumbar (9/30, 30%) and cervical (3/30, 10%).

The median duration of symptoms was 2 months (IQR: 1–4). At presentation, 22 patients (73.3%) had neurological deficits. Neurological Outcomes

### **At baseline:**

- 8 patients (26.7%) had severe deficits (Frankel A–B)
- 14 (46.7%) had moderate deficits (Frankel C–D)
- 8 (26.7%) were neurologically intact (Frankel E)

No significant change was observed in the immediate postoperative period. However, gradual improvement occurred over follow-up.

**At 3 months:**

- 20/30 patients (66.7%) achieved Frankel Grade E
- 18/22 patients (81.8%) with deficits improved by at least one grade

**Pain Outcomes**

Pain improved in all patients. The median Denis pain score reduced from 3 (IQR: 2–4) preoperatively to 1 (IQR: 1–2) at 3 months.

**Symptom Duration and Outcome**

**Patients with shorter symptom duration ( $\leq 2$  months) had:**

- More severe deficits at presentation
- Greater improvement after surgery

**Patients with longer duration ( $>2$  months) had:**

- Better baseline status
- Higher proportion of complete recovery (not statistically significant)

**Tables**

**Table 1. Baseline Characteristics (n = 30)**

Variable	Value
Age (years)	34.2 ± 12.1
Male	19 (63.3%)
Thoracic involvement	18 (60%)
Lumbar involvement	9 (30%)
Cervical involvement	3 (10%)
Neurological deficit	22 (73.3%)

**Table 2. Neurological outcome (Frankel grade)**

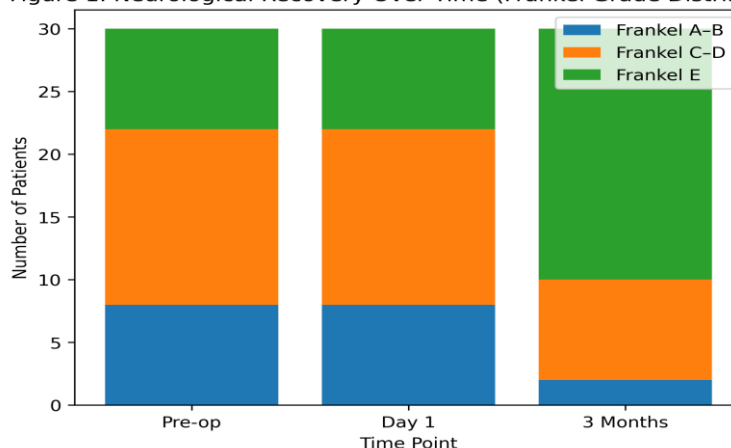
Time point	Frankel A-B	Frankel C-D	Frankel E
Preoperative	8 (26.7%)	14 (46.7%)	8 (26.7%)
Post-op Day 1	8 (26.7%)	14 (46.7%)	8 (26.7%)
3 months	2 (6.7%)	8 (26.7%)	20 (66.7%)

**Table 3. Association of Symptom Duration with Neurological and Pain outcomes**

Variable	$\leq 2$ months (n=15)	$>2$ months (n=15)	Effect size	p-value
Pre-op Frankel grade	2.0 [2.0–3.0]	4.0 [2.0–4.0]	r = -0.44	0.033
$\Delta$ Frankel grade (3 months)	2.0 [1.0–3.0]	1.0 [1.0–2.0]	r = 0.44	0.034
$\Delta$ Denis pain score	2.0 [1.0–2.0]	1.0 [1.0–2.0]	r = 0.30	0.127
Favorable outcome (Grade E)	8/15 (53.3%)	12/15 (80.0%)	OR 0.29 (0.06–1.45)	0.245

Abbreviations:  $\Delta$  = change; OR = odds ratio

**Figure 1. Neurological Recovery Over Time (Frankel Grade Distribution)**



**Figure 1: Distribution of Frankel grades at presentation, immediate postoperative period, and 3-month follow-up demonstrating progressive neurological recovery.**

## **DISCUSSION**

The present prospective study demonstrates that surgical management of spinal tuberculosis leads to significant neurological and pain improvement, with recovery occurring progressively over time rather than immediately after surgery. A key observation was the delayed pattern of neurological recovery, with minimal change in the immediate postoperative period followed by substantial improvement at 3 months. This likely reflects resolution of spinal cord edema, restoration of vascular supply, and gradual neural recovery rather than the effect of decompression alone. Similar temporal patterns have been described previously, suggesting that early postoperative assessment may underestimate final neurological outcome [11,12].

Another important finding was the impact of baseline neurological status on recovery. Patients with severe preoperative deficits demonstrated greater absolute improvement, whereas those with milder deficits were more likely to achieve complete recovery (Frankel Grade E). This highlights that although severe deficits may be reversible, early intervention before advanced neurological compromise offers the best functional outcomes. Preoperative neurological status has consistently been identified as the strongest predictor of outcome in spinal tuberculosis [13–15].

The predominance of thoracic involvement in this study is consistent with established epidemiological patterns, likely related to vascular and biomechanical factors [16]. Pain improvement was observed in all patients, reflecting the effectiveness of surgical decompression and stabilization in addressing both neural compression and spinal instability.

The influence of symptom duration remains complex. In the present study, patients with shorter symptom duration presented with more severe deficits but showed greater postoperative improvement, whereas those with longer duration had better baseline status and higher rates of complete recovery. Although not statistically significant across all measures, this suggests a dynamic relationship between disease progression and neural recovery, as also reported in previous studies [14,17].

From a clinical perspective, these findings support a proactive surgical approach in appropriately selected patients, particularly those with neurological deficits. Additionally, patients should be counseled regarding the gradual nature of neurological recovery, which may extend beyond the early postoperative period.

## **Limitations**

The study is limited by a relatively small sample size and short follow-up duration. Long-term functional outcomes and deformity progression were not assessed. Further studies with larger cohorts and longer follow-up are required.

## **Conclusion**

Surgical management of spinal tuberculosis results in significant neurological recovery and effective pain relief. Neurological improvement is progressive over time, with minimal immediate postoperative change.

Baseline neurological status is the strongest predictor of outcome, with better recovery observed in patients presenting earlier in the disease course. Early surgical intervention in appropriately selected patients improves the likelihood of favorable functional outcomes.

## **Conflict of Interest**

None.

## **Funding**

None.

## **Ethical approval**

The study was approved by the Institutional Ethics Committee, and all procedures were conducted in accordance with the ethical standards of the institutional and national research committee.

## **Informed consent**

Written informed consent was obtained from all patients prior to inclusion in the study.

## **Author Contributions**

All authors contributed substantially to study design, data collection, analysis and manuscript preparation.

## **Acknowledgment**

The authors thank the Department of Neurosurgery and all patients who participated in the study.

## REFERENCES

1. Tuli SM. Tuberculosis of the skeletal system: bones, joints, spine and bursal sheaths. 4th ed. New Delhi: Jaypee Brothers; 2010.
2. Jain AK. Tuberculosis of the spine: a fresh look at an old disease. *J Bone Joint Surg Br.* 2010;92(7):905–913.
3. Garg RK, Somvanshi DS. Spinal tuberculosis: a review. *J Spinal Cord Med.* 2011;34(5):440–454.
4. Moon MS. Tuberculosis of the spine: controversies and a new challenge. *Spine (Phila Pa 1976).* 1997;22(15):1791–1797.
5. Rajasekaran S. Natural history of Pott's kyphosis. *Eur Spine J.* 2013;22(Suppl 4):634–640.
6. Hodgson AR, Stock FE. Anterior spinal fusion for the treatment of tuberculosis of the spine. *J Bone Joint Surg Am.* 1960;42:295–310.
7. Jain AK, Dhammi IK. Tuberculosis of the spine: a review. *Clin Orthop Relat Res.* 2007;460:39–49.
8. Polley P, Dunn R. Noncontiguous spinal tuberculosis: incidence and management. *Eur Spine J.* 2009;18(8):1096–1101.
9. Bhojraj SY, Mehta AC. Tuberculosis of the spine: a review of current concepts. *Indian J Orthop.* 2010;44(4):376–381.
10. Oguz E, Sehirlioglu A, Altinmakas M. A new classification and guide for surgical treatment of spinal tuberculosis. *Int Orthop.* 2008;32(1):127–133.
11. Mehta JS, Bhojraj SY. Tuberculosis of the thoracic spine: surgical strategies. *J Bone Joint Surg Br.* 2001;83(6):859–863.
12. Rajasekaran S, Soundararajan DCR. Progression of neurological deficit in spinal tuberculosis. *Spine J.* 2018;18(10):1875–1882.
13. Jain AK, Kumar J. Tuberculosis of spine: neurological deficit. *Eur Spine J.* 2013;22(Suppl 4):624–633.
14. Moon MS, Woo YK, Lee KS. Posterior instrumentation and anterior interbody fusion for spinal tuberculosis. *Spine (Phila Pa 1976).* 1995;20(17):1910–1916.
15. Zhang HQ, Lin MZ, Li JS. Surgical management of spinal tuberculosis: outcomes and predictors. *Spine (Phila Pa 1976).* 2013;38(13):E830–E838.
16. Wang X, Pang X, Wu P. One-stage posterior approach for thoracic spinal tuberculosis. *Eur Spine J.* 2014;23(8):1771–1778.
17. Shi T, Zhang Z, Dai F. Surgical treatment of spinal tuberculosis: a retrospective study. *Int Orthop.* 2016;40(9):1929–1935.