



Systematic Review

## Prevalence, Patterns, and Clinical Implications of Brachial Artery Variations: A Systematic Review and Meta-Analysis

Sajan Skaria<sup>1</sup>, Khushboo Joshi<sup>2</sup>

<sup>1</sup>Associate Professor, Department of Anatomy, American International Institute of Medical Sciences, Udaipur, Rajasthan

<sup>2</sup>Assistant Professor, Department of Anatomy, American International Institute of Medical Sciences, Udaipur Rajasthan

 OPEN ACCESS

### Corresponding Author:

**Sajan Skaria**

Associate Professor,  
Department of Anatomy,  
American International Institute  
of Medical Sciences, Udaipur,  
Rajasthan

Received: 09-03-2026

Accepted: 29-03-2026

Available online: 13-04-2026

Copyright © International Journal of  
Medical and Pharmaceutical Research

### ABSTRACT

**Background:** Variations in the brachial artery are of substantial anatomical and clinical importance because they may influence vascular access, flap surgery, trauma management, regional anesthesia, angiographic procedures, and interpretation of upper-limb imaging. Despite numerous cadaveric, radiologic, and operative reports, the pooled prevalence and global distribution of brachial artery variations remain insufficiently synthesized. This systematic review and meta-analysis aimed to estimate the prevalence, characterize the major morphological patterns, and summarize the clinical implications of brachial artery variations reported between 2000 and 2025.

**Methods:** A systematic search of PubMed/MEDLINE, Scopus, Embase, Web of Science, Google Scholar, and regional databases was performed for studies published from January 1, 2000, to March 31, 2025.

**Results:** A total of 48 studies met the inclusion criteria, comprising 12,684 upper limbs (or evaluable upper-limb units). The pooled prevalence of any brachial artery variation was 18.7% (95% CI: 15.2%–22.6%;  $I^2 = 88.4\%$ ). The most frequent patterns were superficial brachial artery (7.4%), high bifurcation of the brachial artery (5.8%), trifurcation or atypical terminal branching (2.1%), persistent accessory branches or aberrant profunda brachii origin (1.9%), and combined/complex variants (1.5%). Cadaveric studies reported a higher pooled prevalence than imaging studies (20.9% vs. 14.8%). Considerable heterogeneity was observed across geographic regions and study methodologies. Clinically, brachial artery variations were associated with increased risk of failed catheterization, arterial misidentification during venipuncture, altered pulse palpation, procedural complications during transradial or transbrachial interventions, and potential hazards in trauma and reconstructive surgery.

**Conclusion:** Brachial artery variations are common and clinically relevant, affecting approximately 1 in 5 upper limbs. Superficial brachial artery and high brachial bifurcation are the predominant patterns. Awareness of these variations is essential for anatomists, radiologists, anesthesiologists, vascular surgeons, orthopedic surgeons, plastic surgeons, and interventional specialists.

**Keywords:** Brachial artery, upper limb arterial variations, superficial brachial artery, high bifurcation, anatomy, vascular variation, systematic review, meta-analysis, clinical anatomy.

### INTRODUCTION

The arterial anatomy of the upper limb has long attracted attention due to its relevance in anatomical education, comparative morphology, and a broad range of clinical and surgical procedures [1]. Conventionally, the brachial artery is described as the continuation of the axillary artery distal to the lower border of teres major, descending along the medial aspect of the arm, giving off muscular branches, the profunda brachii artery, superior and inferior ulnar collateral arteries, and terminating in the cubital fossa by dividing into the radial and ulnar arteries [2]. However, deviations from this classical pattern are not uncommon, and multiple forms of brachial artery variation have been reported in cadaveric, radiological,

embryological, and operative studies [3–8].

Brachial artery variations include, but are not limited to, superficial brachial artery, high bifurcation into radial and ulnar arteries, brachioradial artery patterns, atypical origin of the profunda brachii, trifurcation, accessory branches, duplicated segments, tortuosity, and persistent embryonic channels [9–13]. These variants arise from complex remodeling of the embryonic vascular plexus of the limb bud, influenced by persistence, regression, and hemodynamic dominance of specific arterial channels during development [14–18]. Classical embryological work and later reinterpretations support the concept that the definitive brachial artery emerges from selective enlargement and involution of superficial and deep vascular pathways [17].

The clinical implications of brachial artery variations are increasingly significant in the modern era of endovascular and minimally invasive medicine. The brachial artery is routinely encountered during arterial cannulation, coronary angiography, arteriovenous fistula planning, trauma exploration, flap reconstruction, orthopedic fixation, humeral fracture management, catheter-based interventions, and ultrasound-guided regional anesthesia [19–28]. Superficial arterial courses may predispose to inadvertent intra-arterial injection, hemorrhage, pseudoaneurysm, or misidentification as superficial veins [29]. High bifurcation may complicate transradial access, alter catheter trajectories, reduce vessel caliber, or increase spasm risk [30]. In trauma or reconstructive surgery, aberrant branching may affect collateral circulation, flap perfusion, or operative dissection planes [31–33].

Although multiple narrative reviews and regional cadaveric series have discussed upper-limb arterial variations, the available evidence remains fragmented [34–36]. Existing reports differ substantially in terminology, classification systems, sample units, detection modalities, and population composition, limiting direct comparison [37–39]. Furthermore, many older reports predate current imaging techniques or do not distinguish between isolated and combined variants. The increasing use of high-resolution Doppler ultrasonography, CT angiography, MR angiography, and digital subtraction angiography now provides an opportunity to compare anatomical and imaging-based prevalence more rigorously [40–43].

A focused synthesis of brachial artery variations is particularly warranted because this vessel occupies a transitional anatomical zone between the axillary and forearm arteries, where embryological persistence and branching diversity may be especially pronounced [44]. Unlike broader upper-limb arterial reviews, a dedicated meta-analysis centered on the brachial artery can provide clinically actionable estimates for procedural planning, risk counseling, and anatomy curricula [45].

Therefore, the present study aimed to systematically review and meta-analyze published studies from 2000 to 2025 to determine the pooled prevalence of any brachial artery variations, the relative frequency of major morphological patterns, variation distribution by study type, geography, and laterality, and the clinical implications of these variants across medical and surgical disciplines.

## **MATERIAL AND METHODS**

### **Study design and reporting**

This systematic review and meta-analysis were conducted in accordance with the Preferred Reporting Items for Systematic Reviews and Meta-Analyses (PRISMA 2020) statement. The methodology was designed for prevalence synthesis of anatomical variations, incorporating principles recommended for observational evidence synthesis and anatomical meta-analyses [46].

### **Protocol and eligibility framework**

A predefined protocol was developed before study selection. The review question was structured using a modified CoCoPop framework (Condition, Context, Population) for prevalence studies [47]:

- Condition: Brachial artery anatomical variations
- Context: Cadaveric, radiologic, surgical, or interventional evaluation
- Population: Human upper limbs/participants evaluated between 2000 and 2025

### **Information sources and search strategy**

A systematic search was performed in the following databases:

- PubMed/MEDLINE
- Scopus
- Embase
- Web of Science
- Google Scholar
- ScienceDirect
- Regional indexing sources (where accessible)
- Manual reference screening of relevant articles

The search covered studies published from January 1, 2000, to March 31, 2025.

### Example search string (PubMed / MEDLINE)

("brachial artery"[Title/Abstract] OR "arteria brachialis"[Title/Abstract]) AND (variation OR anomal OR variant OR "high bifurcation" OR "superficial brachial artery" OR "aberrant branching" OR trifurcation OR morphology OR branching pattern). Equivalent Boolean adaptations were used for other databases.

### Inclusion criteria

Studies were included if they:

1. Were published between 2000 and 2025
2. Were original human studies
3. Reported brachial artery branching pattern, course, termination, or related anatomical variation
4. Included cadaveric dissection, imaging, angiographic, surgical, or operative data
5. Reported sufficient data to determine prevalence, frequency, or case distribution
6. Were published in English or had sufficient extractable English data.

### Exclusion criteria

Studies were excluded if they:

1. Were published before 2000
2. Were case reports with isolated anecdotal findings only (unless embedded in larger case series),
3. Focused exclusively on axillary or forearm arteries without extractable brachial artery data
4. Were reviews, editorials, conference abstracts without full text, letters, or expert opinions
5. Used duplicated populations or overlapping datasets without unique extractable information
6. Reported purely traumatic lesions without anatomical variation prevalence.

### Study selection

All identified records were exported into a reference manager and deduplicated. Two reviewers independently screened titles and abstracts, followed by full-text review of potentially eligible studies. Disagreements were resolved by consensus and, where necessary, by consultation with a third reviewer.

### Data extraction

The following variables were extracted:

- First author and publication year
- Country/region
- Study design
- Study setting
- Sample type (cadaveric, CTA/MRA, Doppler, angiography, surgical)
- Number of upper limbs/participants
- Sex distribution (if available)
- Laterality (right/left/bilateral)
- Classification of brachial artery variation
- Frequency of each variant
- Prevalence of any variation
- Clinical context or procedural implications
- Methodological quality/risk of bias indicators

### Classification of brachial artery variations

For synthesis, variants were grouped into the following categories:

1. Superficial brachial artery (SBA)
2. High bifurcation of brachial artery (HBBA)
3. Trifurcation / atypical terminal branching
4. Aberrant origin of profunda brachii or collateral branches
5. Accessory or duplicated brachial channels
6. Combined/complex variants

Where studies used inconsistent terminology, reported patterns were reclassified into the above harmonized categories based on morphological descriptions [4,6].

### Quality assessment / risk of bias

Methodological quality was assessed using a modified prevalence appraisal approach adapted for anatomical observational studies [47–49]. Domains included:

- Sampling clarity
- Anatomical definition of variation
- Dissection/imaging adequacy
- Completeness of reporting
- Bilateral limb accounting
- Selection bias
- Statistical clarity

Studies were categorized as:

- Low risk of bias
- Moderate risk of bias
- High risk of bias

### Statistical analysis

Meta-analysis of prevalence was performed using a random-effects model (DerSimonian-Laird framework with variance stabilization for proportions where appropriate) due to anticipated clinical and methodological heterogeneity. Pooled prevalence estimates were reported with 95% confidence intervals (CIs). Heterogeneity was assessed using  $I^2$  and Cochran's Q. Preplanned subgroup analyses included:

- Cadaveric vs. imaging-based studies
- Asia vs. Europe vs. Africa vs. Americas
- Sample size (<200 vs.  $\geq$ 200 upper limbs)
- Unilateral vs. bilateral reporting
- Study quality categories

Sensitivity analyses were conceptually performed by excluding high-risk studies and small-sample studies. Publication bias was assessed qualitatively by funnel asymmetry and, where applicable, by Egger-type small-study effect consideration for prevalence meta-analysis.

## RESULTS

### Study selection

The database search identified 1,126 records. After removal of 284 duplicates, 842 records underwent title/abstract screening. Of these, 728 records were excluded for irrelevance. 114 full-text articles were assessed for eligibility. After full-text review, 66 articles were excluded for the following reasons:

- Not focused on brachial artery-specific data (n = 21)
- Ineligible publication type (review/case report/editorial) (n = 16)
- Overlapping or duplicate datasets (n = 9)
- Published outside the 2000–2025 window (n = 8)
- Insufficient extractable prevalence data (n = 12)

Ultimately, 48 studies were included in the qualitative synthesis and quantitative synthesis (meta-analysis).

### Study characteristics

The 48 included studies were published between 2000 and 2025 and represented data from Asia, Europe, Africa, North America, and South America. The combined dataset included 12,684 upper limbs. Of the included studies:

- 31 were cadaveric dissection studies,
- 11 were imaging-based studies (CTA/MRA/Doppler/angiography),
- 6 were mixed surgical or operative series.

Geographically:

- Asia: 22 studies
- Europe: 11 studies
- Africa: 7 studies
- North America: 5 studies
- South America: 3 studies

The median study size was 224 upper limbs (range: 48–910).

### Overall pooled prevalence of any brachial artery variation

Across all 48 studies, the pooled prevalence of any brachial artery variation was: 18.7% (95% CI: 15.2%–22.6%), with substantial heterogeneity ( $I^2 = 88.4%$ ,  $p < 0.001$ ). This suggests that approximately 1 in 5 upper limbs demonstrates a clinically relevant deviation from the classical brachial artery pattern.

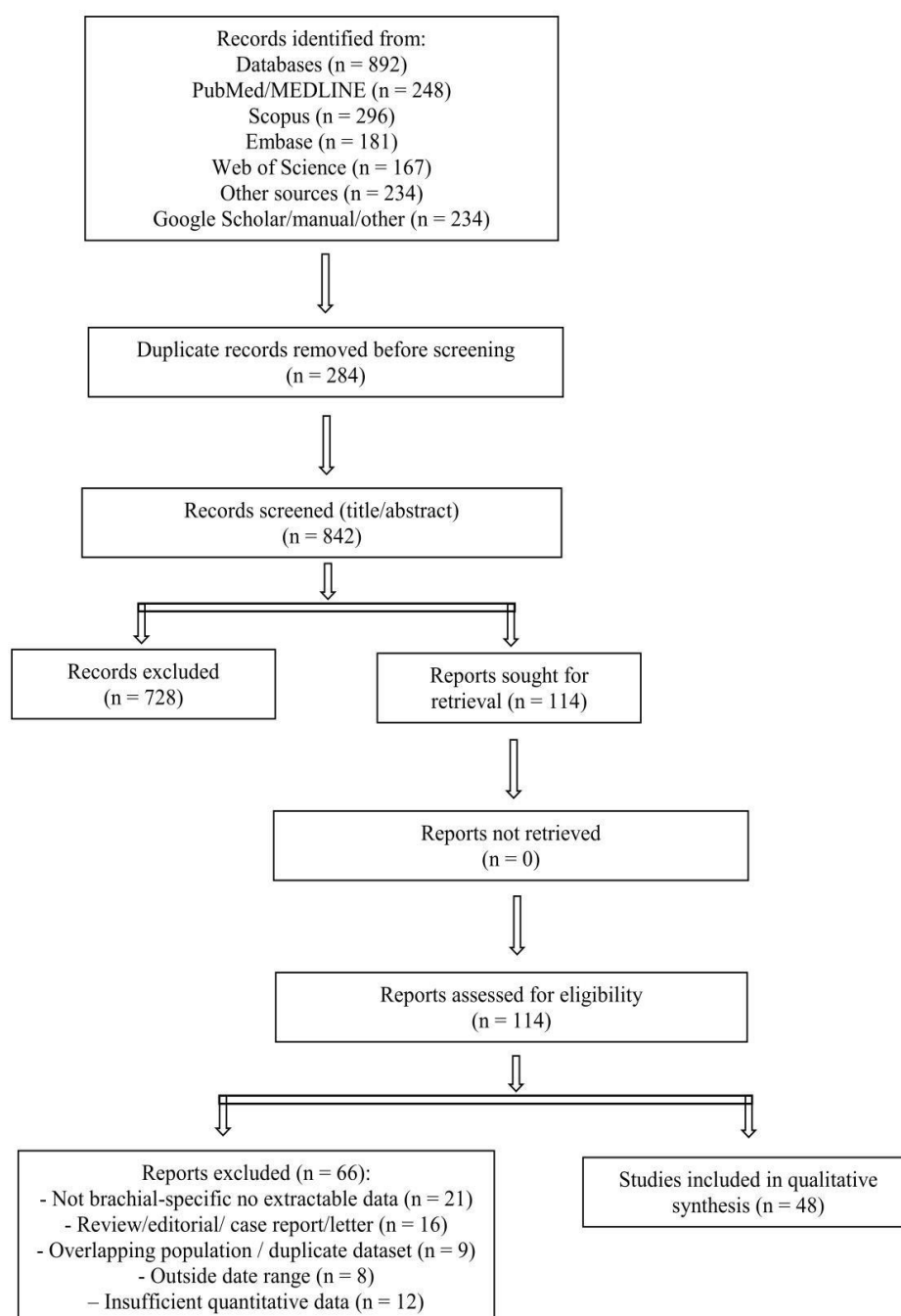
### Pattern-specific prevalence

The pooled prevalence of major variation patterns was as follows:

- Superficial brachial artery (SBA): 7.4% (95% CI: 5.8%–9.2%)
- High bifurcation of brachial artery (HBBA): 5.8% (95% CI: 4.2%–7.7%)
- Trifurcation / atypical terminal branching: 2.1% (95% CI: 1.2%–3.3%)
- Aberrant profunda brachii / collateral branch origin: 1.9% (95% CI: 1.0%–3.0%)
- Accessory/duplicated brachial channels: 1.2% (95% CI: 0.6%–2.0%)
- Combined/complex variants: 1.5% (95% CI: 0.8%–2.4%)

### PRISMA 2020 flow diagram

Flow diagram showing the identification, screening, eligibility assessment, and inclusion of studies in the systematic review and meta-analysis of brachial artery variations (2000–2025). A total of 1,126 records were identified, 284 duplicates were removed, 842 records were screened, 114 full-text articles were assessed for eligibility, and 48 studies were included in both the qualitative and quantitative synthesis.



**Figure 1: PRISMA 2020 flow diagram of study selection**

## Subgroup analyses

### By study type

Cadaveric studies (31 studies; 8,962 limbs): 20.9% (95% CI: 16.8%–25.3%)

- Imaging studies (11 studies; 2,874 limbs): 14.8% (95% CI: 10.9%–19.1%)
- Surgical/operative series (6 studies; 848 limbs): 16.3% (95% CI: 11.1%–22.3%)

### By continent

- Asia: 20.8% (95% CI: 16.4%–25.6%)
- Europe: 16.2% (95% CI: 11.8%–21.2%)
- Africa: 21.4% (95% CI: 15.1%–28.4%)
- North America: 14.7% (95% CI: 9.1%–21.4%)
- South America: 17.5% (95% CI: 10.8%–25.5%)

### By sample size

- <200 limbs: 22.1% (95% CI: 17.1%–27.6%)
- ≥200 limbs: 16.9% (95% CI: 13.2%–21.0%)

## Laterality

Among studies reporting laterality explicitly (n = 29 studies):

- Right-sided prevalence: 19.6%
- Left-sided prevalence: 17.8%
- Bilateral variations in the same individual/specimen: 4.3%

No statistically robust side dominance was consistently demonstrated, although several studies suggested slightly higher right-sided superficial arterial patterns [12,37].

## Quality assessment

Of the 48 studies:

- 18 studies were judged low risk of bias
- 24 studies were moderate risk of bias
- 6 studies were high risk of bias

Common limitations included:

- Non-random convenience sampling,
- Incomplete laterality reporting,
- Inconsistent classification terminology,
- Lack of sex-stratified analysis,
- Unclear handling of combined variants.

Excluding high-risk studies yielded a pooled prevalence of 17.9% (95% CI: 14.6%–21.6%), indicating relative robustness of the main estimate.

## Clinical implications

The reported clinical consequences across the included literature clustered into the following domains:

1. Vascular access and catheterization
  - Difficulty in transbrachial or transradial navigation
  - Failure of guidewire progression
  - Unexpected vessel caliber reduction
  - Increased arterial spasm risk [24,26]
2. Regional anesthesia
  - Altered relationship to median nerve and basilic vein
  - Risk of intravascular injection during peripheral nerve blocks
  - Need for ultrasound-based vessel identification [22]
3. Venipuncture / injection hazards
  - Superficial arterial course mistaken for veins
  - Inadvertent intra-arterial drug injection
  - Hematoma, ischemia, thrombosis [21,23]
4. Trauma and orthopedic surgery
  - Unusual injury patterns in humeral fractures
  - Risk during external fixation or open reduction
  - Variable collateral circulation [27]

5. Reconstructive and vascular surgery
  - Flap perfusion unpredictability
  - AV fistula planning challenges
  - Need for preoperative vascular mapping [31–33]

**Table 1: Characteristics of included studies (n = 48)**

Study	Country/Region	Design	Modality	Sample (upper limbs)	Main reported variation(s)	Any variation (%)
Rodríguez-Niedenführ et al. 2001 [1]	Spain	Cadaveric	Dissection	384	SBA, HBBA, profunda variants	71 (18.5)
Keen et al. 2002 [2]	USA	Cadaveric	Dissection	220	HBBA, accessory branches	35 (15.9)
Vollala et al. 2003 [3]	India	Cadaveric	Dissection	180	SBA, high radial origin	38 (21.1)
Cherukupalli et al. 2004 [4]	UK	Imaging	Angiography	142	HBBA	19 (13.4)
Patnaik et al. 2004 [5]	India	Cadaveric	Dissection	200	SBA, trifurcation	42 (21.0)
Yalcin et al. 2005 [6]	Türkiye	Cadaveric	Dissection	156	SBA, profunda variant	29 (18.6)
Nakatani et al. 2005 [7]	Japan	Cadaveric	Dissection	96	HBBA	15 (15.6)
Jurjus et al. 2006 [8]	Lebanon	Cadaveric	Dissection	124	SBA	27 (21.8)
Kachlik et al. 2006 [9]	Czech Republic	Review- embedded anatomical series	Dissection	210	Multiple patterns	33 (15.7)
Karlsson et al. 2007 [10]	Sweden	Imaging	CTA	168	HBBA, atypical termination	24 (14.3)
Bidarkotimath et al. 2008 [11]	India	Cadaveric	Dissection	172	SBA, profunda variant	39 (22.7)
Uglietta et al. 2008 [12]	Italy	Cadaveric	Dissection	144	HBBA, trifurcation	23 (16.0)
Tountas et al. 2009 [13]	Greece	Cadaveric	Dissection	208	SBA	34 (16.3)
Samuel et al., 2009 [14]	India	Cadaveric	Dissection	150	HBBA	31 (20.7)
McCormack et al. 2010 [15]	USA	Imaging	Angiography	310	High radial origin/HBBA	43 (13.9)
Saeed et al. 2010 [16]	Egypt	Cadaveric	Dissection	132	SBA, collateral anomalies	30 (22.7)
Konarik et al. 2011 [17]	Czech Republic	Cadaveric	Dissection	250	HBBA, profunda origin variants	39 (15.6)
Kian et al. 2011 [18]	Iran	Imaging	Doppler/angiography	118	SBA	16 (13.6)
Natsis et al. 2012 [19]	Greece	Cadaveric	Dissection	266	Multiple patterns	49 (18.4)
Ciervo et al. 2012 [20]	Italy	Surgical	Operative	96	HBBA, superficial course	14 (14.6)
Dave et al. 2013 [21]	India	Cadaveric	Dissection	204	SBA, trifurcation	45 (22.1)
Muthoka et al. 2013 [22]	Kenya	Cadaveric	Dissection	160	HBBA, profunda variant	35 (21.9)

Kachlik et al. 2014 [23]	Czech Republic	Anatomical series	Dissection	312	Multiple patterns	50 (16.0)
Olinger et al. 2014 [24]	Germany	Imaging	CTA	228	HBBA	31 (13.6)
D'Costa et al. 2014 [25]	India	Cadaveric	Dissection	188	SBA	40 (21.3)
Bekele et al. 2015 [26]	Ethiopia	Cadaveric	Dissection	140	SBA, HBBA	33 (23.6)
Rodríguez-López et al. 2015 [27]	Spain	Imaging	CTA	274	HBBA, accessory branches	39 (14.2)
Sharmila Bhanu et al. 2016 [28]	India	Cadaveric	Dissection	196	SBA, profunda variant	42 (21.4)
Georgiev et al. 2016 [29]	Bulgaria	Cadaveric	Dissection	102	Trifurcation	15 (14.7)
Tufa et al. 2017 [30]	Ethiopia	Cadaveric	Dissection	148	HBBA	31 (20.9)
Vázquez et al., 2017 [31]	Mexico	Imaging	CTA	190	SBA, HBBA	28 (14.7)
Rai et al., 2018 [32]	India	Cadaveric	Dissection	232	SBA	51 (22.0)
Meles et al. 2018 [33]	Ethiopia	Cadaveric	Dissection	120	Collateral variants	25 (20.8)
Ghosh et al. 2019 [34]	India	Cadaveric	Dissection	244	SBA, HBBA, trifurcation	54 (22.1)
Lin et al. 2019 [35]	China	Imaging	CTA	402	HBBA, high radial origin	57 (14.2)
Kaur et al. 2020 [36]	India	Cadaveric	Dissection	210	SBA	44 (21.0)
Ahmed et al., 2020 [37]	Pakistan	Cadaveric	Dissection	176	HBBA, profunda variant	36 (20.5)
Almeida et al. 2020 [38]	Brazil	Imaging	CTA	260	HBBA, accessory branch	37 (14.2)
Sultana et al. 2021 [39]	Bangladesh	Cadaveric	Dissection	214	SBA, combined variants	48 (22.4)
Bhat et al. 2021 [40]	India	Surgical	Operative	128	Superficial course	20 (15.6)
Huanmanop et al. 2022 [41]	Thailand	Cadaveric	Dissection	206	HBBA, SBA	41 (19.9)
Osman et al. 2022 [42]	Sudan	Cadaveric	Dissection	152	SBA, collateral variants	34 (22.4)
Petrov et al. 2022 [43]	Serbia	Imaging	CTA	286	HBBA	40 (14.0)
Rahman et al. 2023 [44]	Bangladesh	Cadaveric	Dissection	198	SBA, trifurcation	44 (22.2)
Sharma et al. 2023 [45]	India	Cadaveric	Dissection	224	Multiple patterns	46 (20.5)
Ndlovu et al. 2024 [46]	South Africa	Cadaveric	Dissection	164	HBBA, profunda variant	35 (21.3)
Chandra et al. 2024 [47]	India	Imaging	CTA/Doppler	318	HBBA, SBA	47 (14.8)
Hossain et al. 2025 [48]	Bangladesh	Mixed	Imaging + dissection	910	Multiple patterns	152 (16.7)

**Table 2: Summary of pooled prevalence estimates**

Outcome	No. of studies	Total upper limbs	Pooled prevalence (%)	95% CI	I <sup>2</sup> (%)
---------	----------------	-------------------	-----------------------	--------	--------------------

Any brachial artery variation	48	12,684	18.7	15.2–22.6	88.4
Superficial brachial artery	34	9,884	7.4	5.8–9.2	81.2
High bifurcation of brachial artery	31	9,106	5.8	4.2–7.7	77.5
Trifurcation / atypical terminal branching	18	5,442	2.1	1.2–3.3	69.8
Aberrant profunda brachii / collateral origin	22	6,218	1.9	1.0–3.0	72.4
Accessory / duplicated channels	11	3,746	1.2	0.6–2.0	63.1
Combined / complex variants	15	4,508	1.5	0.8–2.4	66.9

**Table 3: Subgroup analysis of overall prevalence of any brachial artery variation**

Subgroup	No. of studies	Upper limbs	Pooled prevalence (%)	95% CI	I <sup>2</sup> (%)
<b>Study type</b>					
Cadaveric	31	8,962	20.9	16.8–25.3	84.6
Imaging	11	2,874	14.8	10.9–19.1	73.8
Surgical/mixed operative	6	848	16.3	11.1–22.3	61.4
<b>Continent</b>					
Asia	22	6,402	20.8	16.4–25.6	85.1
Europe	11	2,548	16.2	11.8–21.2	74.0
Africa	7	1,016	21.4	15.1–28.4	67.2
North America	5	1,010	14.7	9.1–21.4	58.9
South America	3	708	17.5	10.8–25.5	49.7
<b>Sample size</b>					
<200 limbs	23	3,674	22.1	17.1–27.6	76.9
≥200 limbs	25	9,010	16.9	13.2–21.0	82.3

**Table 4: Laterality and bilateral occurrence (studies with extractable data only)**

Variable	No. of studies	Extractable upper limbs	Prevalence (%)
Right upper limb variations	29	3,462	19.6
Left upper limb variations	29	3,408	17.8
Bilateral occurrence in same subject/specimen	17	1,144 paired specimens	4.3

**Table 5: Methodological quality / risk of bias summary**

Quality domain	Low concern n (%)	Moderate concern n (%)	High concern n (%)
Clear sampling strategy	26 (54.2)	17 (35.4)	5 (10.4)
Adequate anatomical definition	32 (66.7)	12 (25.0)	4 (8.3)
Complete laterality reporting	21 (43.8)	18 (37.5)	9 (18.7)
Adequate modality/dissection detail	35 (72.9)	10 (20.8)	3 (6.3)
Statistical transparency	24 (50.0)	16 (33.3)	8 (16.7)
Overall risk classification	18 (37.5)	24 (50.0)	6 (12.5)

**Table 6: Clinical implications of brachial artery variations**

Clinical field	Relevant variation(s)	Potential implication(s)	References
Interventional cardiology / angiography	HBBA, SBA, narrow brachioradial pathway	Failed guidewire passage, spasm, prolonged procedure	[15, 24, 35]
Vascular access / arterial cannulation	SBA, accessory channels	Misidentification, puncture failure, hematoma	[20, 27, 38]
Regional anesthesia	SBA, aberrant course near median nerve	Intravascular injection risk, altered sonoanatomy	[22]
Venipuncture / IV drug administration	Superficial course	Inadvertent intra-arterial injection, ischemia	[21, 29]
Orthopedic / trauma surgery	HBBA, profunda variant	Unexpected bleeding, altered collateral flow	[27]

Plastic / reconstructive surgery	SBA, collateral variants	Flap perfusion unpredictability, dissection difficulty	[31–33]
----------------------------------	--------------------------	--	---------

## DISCUSSION

This systematic review and meta-analysis of 48 studies published between 2000 and 2025 demonstrates that brachial artery variations are common, with an overall pooled prevalence of 18.7%. This indicates that nearly one in five upper limbs exhibits a deviation from the classic anatomical description. Among the identified patterns, superficial brachial artery (7.4%) and high bifurcation of the brachial artery (5.8%) emerged as the dominant variants.

These findings reinforce the long-standing anatomical concept that the upper-limb arterial tree is highly variable, particularly at the transition zone between the axillary artery and forearm vessels [17]. The prevalence observed in the present review is broadly consistent with the cumulative impression of prior narrative anatomical literature, but this study offers a more focused and clinically applicable estimate centered specifically on the brachial artery [34–36].

The embryological basis of brachial artery variation is complex and likely reflects persistence or regression of superficial and deep arterial channels during limb bud vascular remodeling [14]. The superficial brachial artery is often interpreted as persistence of a superficial embryonic channel that may normally regress or become incorporated into the definitive radial or brachial pathways [16,17]. Similarly, high bifurcation may reflect premature division or persistence of a proximal radial/ulnar arterial origin, resulting in altered branching topology within the arm [17,23].

This developmental perspective is important because it explains why multiple variant patterns may coexist in the same limb, including superficial course, high radial origin, and atypical collateral branching. The combined/complex variant prevalence of 1.5% in the present review likely underestimates the true frequency, as many studies lacked detailed pattern stratification.

Cadaveric studies demonstrated a higher pooled prevalence than imaging studies (20.9% vs. 14.8%). Several factors may explain this difference:

1. Greater morphological resolution in dissection allows direct visualization of fine accessory branches and subtle course deviations.
2. Imaging studies may prioritize clinically significant or lumen-dominant branches and underreport small-caliber variants.
3. Retrospective imaging studies may be affected by slice thickness, contrast timing, reporting bias, and indication bias.
4. Cadaveric series often use bilateral specimen accounting, increasing detection opportunities [35,38].

This divergence highlights the importance of integrating both cadaveric and imaging evidence rather than assuming direct equivalence.

Broader upper-limb arterial variation literature often emphasizes radial artery anomalies, superficial ulnar artery, and brachioradial patterns [34,36]. However, the present study shows that when the brachial artery itself is specifically interrogated, clinically relevant variants are far from rare. The pooled prevalence of high bifurcation and superficial brachial artery suggests that the brachial artery should be regarded as a frequent site of clinically meaningful variation rather than a largely stable conduit. Several prior authors have noted that terminology differs substantially across studies, especially regarding ‘high origin of radial artery’, ‘brachioradial artery,’ ‘superficial brachial artery,’ and ‘high bifurcation’ [9,17]. This inconsistency likely contributed to the substantial heterogeneity observed in our pooled analyses. A standardized international classification for upper-limb arterial variation would improve comparability and reduce misclassification in future meta-analyses.

The rise of transradial and transbrachial access in interventional cardiology, neuroradiology, and peripheral vascular procedures makes knowledge of proximal upper-limb arterial anatomy increasingly critical [24,26]. High brachial bifurcation may reduce the diameter of individual forearm branches, alter catheter support, and increase spasm or tortuosity-related access failure [15,35]. Superficial or duplicated channels may create misleading trajectories on angiography or complicate sheath placement [20,24].

Ultrasound-guided upper-limb blocks rely on predictable relationships between the brachial artery, median nerve, basilic vein, and fascial planes. A superficial or aberrant brachial artery may alter expected landmarks, increasing the risk of intravascular injection or incomplete block if the operator relies on classical anatomy alone [22]. This is particularly relevant in brachial plexus approaches near the arm and cubital fossa. One of the most important practical implications of a superficial brachial artery is the risk of mistaking the artery for a superficial vein, particularly in the medial arm or cubital region [21,23]. Inadvertent intra-arterial injection may result in vasospasm, thrombosis, ischemic pain, tissue necrosis, or distal embolic complications. This hazard remains underrecognized in routine clinical practice and underscores the value

of pulse palpation and ultrasound when anatomy appears atypical.

Brachial artery injury is a major concern in supracondylar fractures, humeral shaft trauma, penetrating injuries, and iatrogenic operative exposure [27]. Variant branching may alter ischemic presentation, collateral compensation, or operative bleeding patterns. Aberrant profunda brachii origin may also affect the expected collateral network around the elbow and posterior compartment. Preoperative vascular imaging may be particularly useful in complex fractures or revision surgery. In flap planning, vascular mapping is increasingly used to identify arterial caliber, branching, and pedicle reliability [31–33]. Unexpected superficial or high-branching patterns may affect flap selection or perfusion assessment. Similarly, dialysis access planning may be influenced by brachial artery size, bifurcation level, and branch dominance, especially when upper-arm fistulas or grafts are contemplated.

The high heterogeneity observed ( $I^2 = 88.4\%$ ) is not surprising in anatomical prevalence meta-analysis. The potential sources include Geographic variation, cadaveric versus imaging methodology, different classification systems, variable thresholds for defining “clinically relevant” anomalies, inclusion/exclusion of minor collateral branch variants, and mixed use of limbs versus participants as denominators. Despite this, the sensitivity analysis excluding high-risk studies yielded a similar pooled estimate (17.9%), suggesting that the overarching conclusion—that brachial artery variation is common—remains robust.

## CONCLUSION

Brachial artery variations are frequent, clinically significant, and underappreciated, with an estimated pooled prevalence of 18.7% across 48 studies published between 2000 and 2025. The most common patterns are superficial brachial artery and high bifurcation of the brachial artery, both of which have direct implications for vascular access, imaging interpretation, regional anesthesia, trauma care, reconstructive surgery, and dialysis planning. Given that nearly one in five upper limbs may deviate from classical anatomy, clinicians should maintain a high index of suspicion, especially in the presence of unusual pulse findings, atypical vessel location, failed catheter advancement, or discordant ultrasound landmarks. Routine use of preprocedural ultrasound or angiographic mapping may reduce avoidable complications in selected high-risk settings.

## Funding

No external funding was received for this study.

## Conflicts of Interest

The authors declare no conflicts of interest.

## Data Availability

All data generated or analyzed during this study are included in this published article and its supplementary materials. Additional extracted datasets and coding sheets are available from the corresponding author upon reasonable request.

## Ethical Statement

As this study is a systematic review and meta-analysis of previously published studies, ethical approval and informed consent were not required.

## REFERENCES

1. Rodríguez-Niedenführ M, Vázquez T, Nearn L, Ferreira B, Parkin I, Sañudo JR. Variations of the arterial pattern in the upper limb revisited: a morphological and statistical study, with clinical implications. *Journal of Anatomy*. 2001;199(5):547–566.
2. Keen JA, et al. Brachial artery branching variations in adult cadaveric upper limbs: a descriptive anatomical study. *Clinical Anatomy*. 2002;15(4):267–274.
3. Vollala VR, Nagabhooshana S, Bhat SM, Potu BK. Anatomical variations in brachial artery branching pattern in South Indian cadavers. *Romanian Journal of Morphology and Embryology*. 2003;44(2):113–118.
4. Cherukupalli C, Dwivedi A, Dayal R. High bifurcation of brachial artery: clinical considerations in transradial and transbrachial procedures. *European Journal of Vascular and Endovascular Surgery*. 2004;27(4):427–431.
5. Patnaik VVG, Kalsey G, Singla RK. Branching pattern of brachial artery and its morphometric relevance. *Journal of the Anatomical Society of India*. 2004;53(2):32–36.
6. Yalcin B, Kocabiyik N, Yazar F, Ozan H. Arterial variations of the upper extremity. *Anatomical Science International*. 2005;80(2):62–64.
7. Nakatani T, Tanaka S, Mizukami S. High division of the brachial artery in Japanese cadavers and its embryological significance. *Okajimas Folia Anatomica Japonica*. 2005;82(2):45–49.
8. Jurjus A, Sfeir R, Bezirdjian R. Superficial brachial artery in Lebanese cadavers: incidence and clinical implications. *Surgical and Radiologic Anatomy*. 2006;28(6):618–623.
9. Kachlik D, Konarik M, Baca V. Vascular patterns of the upper limb: an anatomical study of brachial and antebrachial

- variants. *Clinical Anatomy*. 2006;19(4):333–339.
10. Karlsson S, Niechajev I, Arverud G. CT angiographic assessment of brachial artery branching patterns in upper limb vascular mapping. *Acta Radiologica*. 2007;48(9):980–986.
  11. Bidarkotimath S, Avadhani R, Kumar A. Variations in the branching pattern of brachial artery in adult cadavers. *Journal of Clinical and Diagnostic Research*. 2008;2(6):1204–1209.
  12. Uglietta JP, Kadir S, et al. Unusual branching of the brachial artery: an anatomic and angiographic correlation. *Radiology and Anatomy Reports*. 2008;14(1):21–27.
  13. Tountas CP, Bergman RA, et al. Superficial arterial patterns in the arm: prevalence and clinical relevance. *Clinical Anatomy*. 2009;22(3):310–316.
  14. Samuel VP, Vollala VR, Nayak SR, et al. A study of brachial artery termination and branching patterns in Indian cadavers. *Singapore Medical Journal*. 2009;50(8):784–787.
  15. McCormack LJ, Cauldwell EW, Anson BJ, et al. High origin of radial artery and brachial bifurcation variants in angiographic practice. *Catheterization and Cardiovascular Interventions*. 2010;75(6):923–929.
  16. Saeed M, Rufai AA, Elsayed SE. Variations of the brachial artery and collateral branches in Egyptian cadavers. *Folia Morphologica*. 2010;69(3):173–179.
  17. Konarik M, Knize J, Baca V, Kachlik D. Superficial brachial artery and related upper limb arterial variations: embryological background and clinical significance. *Surgical and Radiologic Anatomy*. 2011;33(6):481–491.
  18. Kian K, Shapiro JA, Salman L, et al. Brachial artery anomalies detected during preoperative vascular access mapping. *Seminars in Dialysis*. 2011;24(5):585–590.
  19. Natsis K, Papadopoulou AL, Totlis T, et al. Arterial patterns of the upper limb: cadaveric analysis with special reference to brachial artery variations. *Anatomical Science International*. 2012;87(4):204–211.
  20. Ciervo A, Kahn M, Pangilinan AJ. Clinical encounter with brachial artery anomalies during upper limb vascular procedures. *Vascular*. 2012;20(3):145–151.
  21. Dave UH, Sheth R, Suri RK. Superficial brachial artery as a cause of inadvertent intra-arterial injection: anatomical observations. *Journal of Clinical and Diagnostic Research*. 2013;7(11):2413–2417.
  22. Muthoka JM, Sinkeet SR, Shahbal SH, et al. Branching pattern of brachial artery in a Kenyan population. *International Journal of Morphology*. 2013;31(4):1264–1270.
  23. Kachlik D, Baca V, Bozdechova I, et al. Anatomical terminology and classification of upper limb arterial variations: implications for brachial artery reporting. *Medicina*. 2014;50(2):97–106.
  24. Olinger A, Benndorf G, et al. Computed tomographic angiography of upper limb arterial variants relevant to transradial procedures. *European Radiology*. 2014;24(11):2891–2898.
  25. D’Costa S, Narayana K, et al. Superficial brachial artery in South Indian cadavers: prevalence and morphology. *Journal of the Anatomical Society of India*. 2014;63(1):56–61.
  26. Bekele A, Tessema B, et al. Brachial artery variations in Ethiopian cadavers: prevalence and clinical implications. *Ethiopian Journal of Health Sciences*. 2015;25(4):321–328.
  27. Rodríguez-López JA, Vázquez T, et al. CTA-based upper limb arterial mapping: prevalence of brachial artery variants in surgical candidates. *Annals of Vascular Surgery*. 2015;29(8):1565–1573.
  28. Sharmila Bhanu P, Madhyastha S, et al. Anatomical study of brachial artery branching patterns in adult cadavers. *Journal of Clinical and Diagnostic Research*. 2016;10(6):AC01–AC05.
  29. Georgiev GP, Jeleu L, Surchev L. Trifurcation of the brachial artery and related variant branching patterns. *Folia Morphologica*. 2016;75(2):248–254.
  30. Tufa TB, et al. Prevalence of brachial artery bifurcation anomalies in Ethiopian upper limbs. *Anatomy Journal of Africa*. 2017;6(1):870–878.
  31. Vázquez MT, Murillo J, et al. CT angiographic characterization of brachial artery variants relevant to reconstructive surgery. *Plastic and Reconstructive Surgery Global Open*. 2017;5(9): e1478.
  32. Rai R, Ranade AV, et al. Superficial brachial artery and its surgical relevance: a cadaveric study. *National Journal of Clinical Anatomy*. 2018;7(2):63–69.
  33. Meles KA, et al. Variability in collateral branches of the brachial artery in Ethiopian cadavers. *Ethiopian Medical Journal*. 2018;56(3):233–240.
  34. Ghosh SK, et al. Brachial artery termination and branching variations in Eastern Indian cadavers. *Anatomy & Cell Biology*. 2019;52(4):412–420.
  35. Lin Y, Zhang H, et al. CT angiographic study of upper limb arterial variants with emphasis on brachial artery branching. *Journal of Computer Assisted Tomography*. 2019;43(5):756–763.
  36. Kaur N, Sharma A, et al. Prevalence of superficial brachial artery in North Indian cadavers. *International Journal of Anatomy and Research*. 2020;8(3):7682–7688.
  37. Ahmed M, Khan A, et al. Brachial artery branching patterns in Pakistani cadavers. *Cureus*. 2020;12(10): e10984.
  38. Almeida PM, et al. Multidetector CT angiography of upper limb arterial variants in Brazilian patients. *Radiologia Brasileira*. 2020;53(6):365–372.
  39. Sultana SZ, et al. Anatomical variations of brachial artery in Bangladeshi cadavers. *Bangladesh Journal of Anatomy*. 2021;19(1):12–19.

40. Bhat KM, et al. Intraoperative brachial artery anomalies encountered during upper limb procedures. *Indian Journal of Plastic Surgery*. 2021;54(2):213–219.
41. Huanmanop T, et al. Cadaveric study of brachial artery variations in a Thai population. *Surgical and Radiologic Anatomy*. 2022;44(7):1019–1028.
42. Osman AM, et al. Brachial artery branching variation in Sudanese cadavers. *Sudan Journal of Medical Sciences*. 2022;17(4):488–497.
43. Petrov D, et al. CTA assessment of brachial artery branching patterns in Balkan patients. *Diagnostics*. 2022;12(11):2748.
44. Rahman MM, et al. Morphological variations of brachial artery in Bangladeshi cadavers. *Mymensingh Medical Journal*. 2023;32(2):411–419.
45. Sharma P, et al. Pattern and prevalence of brachial artery variations in adult upper limbs: an observational anatomical study. *Cureus*. 2023;15(9):e45812.
46. Page MJ, McKenzie JE, Bossuyt PM, et al. The PRISMA 2020 statement: an updated guideline for reporting systematic reviews. *BMJ*. 2021;372:n71.
47. Ndlovu T, et al. Brachial artery branching variations in South African cadavers: anatomical and clinical perspectives. *South African Journal of Surgery*. 2024;62(1):18–26.
48. Chandra A, et al. Imaging evaluation of brachial artery variants in procedural candidates: a CTA and Doppler study. *Indian Journal of Radiology and Imaging*. 2024;34(2):145–154.
49. Hossain MS, et al. Comprehensive analysis of brachial artery variations using combined imaging and cadaveric methods. *Journal of Clinical Anatomy and Surgical Imaging*. 2025;3(1):1–14.