



Case Report

Eccrine Hydrocystoma: A Rare Diagnostic Challenge in Facial Adnexal Lesions of Paediatric Age Group

Dr Hiral Chavda¹, Dr Kirti Vyas²

¹Dr. N. D. Desai faculty of medical science and research, Nadiad, Kheda, Gujarat, India.

²MD Pathology, Head of dept. of Pathology

 OPEN ACCESS

Corresponding Author:

Dr Hiral Chavda

Dr. N. D. Desai faculty of medical science and research, Nadiad, Kheda, Gujarat, India.

Email: hir.98127@gmail.com

Received: 19-02-2026

Accepted: 25-03-2026

Published: 11-04-2026

Copyright© International Journal of
Medical and Pharmaceutical Research

ABSTRACT

Purpose: To describe clinical presentation, histopathological results and clinical significance of early diagnosis and management of eccrine hydrocystoma in paediatric patient. Eccrine hydrocystoma is a small translucent benign cyst which occurs as a result of dilated ducts of mature eccrine sweat unit. It is a rare, benign ductal retention cyst of sweat glands, most often arising in the periocular region and often enlarge in conditions that stimulate perspiration. They can clinically mimic other adnexal lesions, making histopathological confirmation essential. We report a case of a 7-year-old male who presented with a progressively enlarging, painless swelling of the left upper eyelid for four months, associated with drooping of the lid. Provisional diagnosis included hematoma and haemangioma. The lesion was surgically excised under general anaesthesia. Histopathology confirmed diagnosis of eccrine hydrocystoma. Postoperatively, the patient recovered well, with no recurrence or complications over a 2-month follow-up period. This case highlights eccrine hydrocystoma as an important differential diagnosis of eyelid cystic lesions in paediatric patients which is more common in middle aged female patients generally. Complete surgical excision provides both diagnosis and cure with excellent prognosis.

Keywords: child, eccrine hydrocystoma, cyst, facial adnexal lesion.

INTRODUCTION

Eccrine Hydrocystoma is a rare, benign ductal retention cyst of sweat glands, most often arising in the periocular region, lower eye lid or scalp which occurs as a result of dilated ducts of mature eccrine sweat unit and often enlarge in conditions that stimulate perspiration. They are most commonly solitary, unilocular cyst with clear to brown fluid in the cyst lumen. Cysts are lined by bilayer cuboidal cells with no decapitation secretion or snouts. They typically affect males and females equally. Lesion typically ranges from 1 to 3 mm in diameter but may continue to grow until surgical intervention or trauma. They can clinically mimic other adnexal lesions, making histopathological confirmation essential.

CASE REPORT

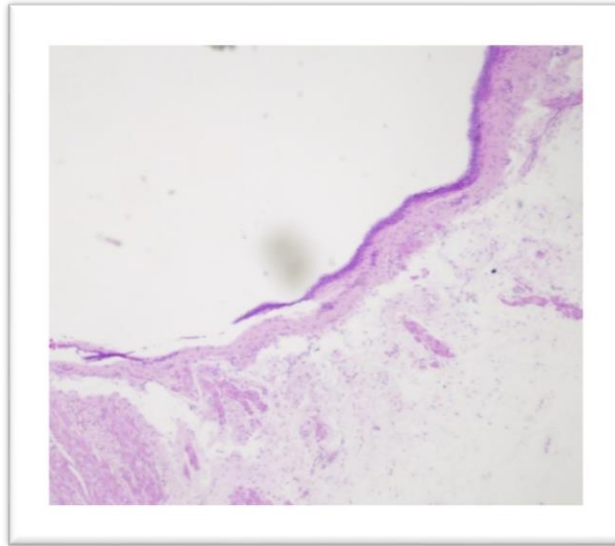
A 7-year-old male who presented with a progressively enlarging, painless swelling of the left upper eyelid for four months, associated with drooping of the lid. Clinical examination revealed a 20 × 10 × 10 mm soft, non-tender, immobile cystic lesion away from the eyelid margin. Provisional diagnosis included hematoma and haemangioma. The lesion was surgically excised under general anaesthesia.

GROSS EXAMINATION

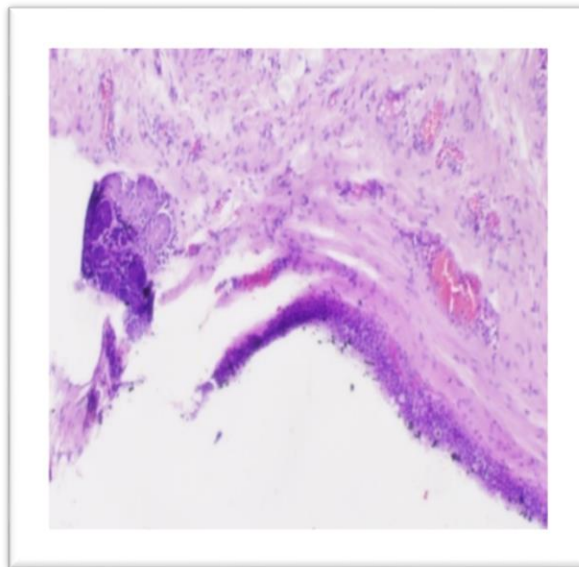
We received a single, whitish, cystic soft to firm tissue measuring 2.3 x 1.0 cm. On cutting open transparent clear fluid came out and multiple cystic areas are seen.

MICROSCOPIC EXAMINATION

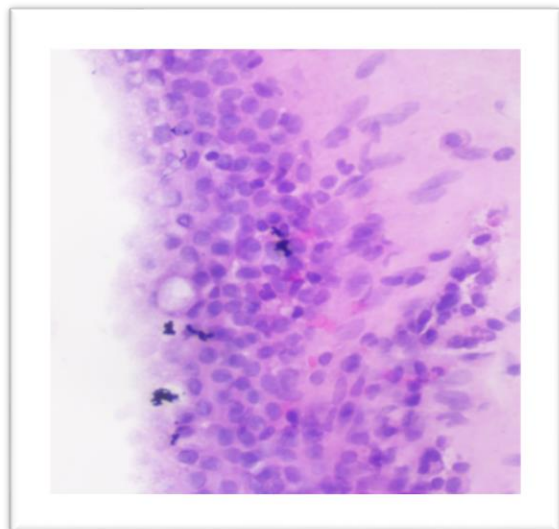
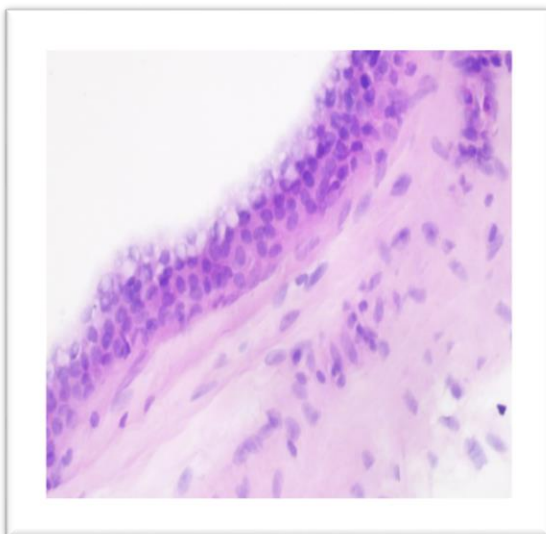
It revealed a cyst surrounded by fibromuscular tissue and congested blood vessels. The cyst is lined by flat to cuboidal to multilayer epithelium with inner layer of eosinophilic Cells without decapitation. At places goblet cells are seen. A focus of small lobule of lacrimal gland tissue also seen.



H & E stain, 4x



Microphotograph shows cyst lining surrounded by fibromuscular tissue and congested blood vessels. H & E stain(10x)



Microscopy shows the cyst lined by cuboidal to multilayer epithelium with inner layer of eosinophilic cells without decapitation .H & E stain(40x)

DIAGNOSIS

The diagnosis was benign eyelid cyst, eccrine hydrocystoma of left eye.

post operatively, there was mild lid edema, the suture site was healthy. The Patient was followed for 2 months. There were no recurrence, wound infection, or any other operative site complications at 1 and 2 months of follow-up.

DISSCUSSION

Eccrine hydrocystomas are small translucent, fluid-filled cysts of eccrine duct origin. They are considered to be ductal retention cysts, and often enlarge in conditions that stimulate perspiration. There are generally two types, Solitary (Smith) and multiple (Robinson). (Hodge et al., 2026)

- **Solitary lesions** present as skin-colored dome-shaped papules in the periorbital area usually located along the lower eyelids and canthi near but not directly involving the eyelid margin.
- **Multiple** type lesions are smaller in diameter and predominantly affect women in the periorbital and malar areas. They are associated with conditions that cause hyperhidrosis and often exacerbated by hot and humid environments. Multiple eccrine hydrocystoma has been reported to be associated with Graves' disease, Parkinson's disease, idiopathic craniofacial hyperhidrosis, and prolactinoma. (Alfadley et al., 2001)

Our differential diagnosis was epidermal cyst, dermoid cyst, lacrimal gland cyst, eccrine hydrocystoma, apocrine hydrocystoma.

Epidermal cyst is benign cystic lesion most commonly seen on face, neck, trunk. It can be found in any age. Epidermal cysts are generally painless, presents with central punctum. It can get inflamed and infected turning painful and can get ruptured due to frequent irritation and recurrent infection. Cyst lumen is filled with keratin flakes which grossly appears as a malodorous, cheesy, dirty material where as in this case, cyst was filled with clear transparent fluid. Histopathological examination shows cyst lined by squamous epithelium with lumen containing keratin flakes. Both gross and microscopic findings help to rule out epidermal cyst.

Dermoid cyst is derived from ectoderm, mesoderm and endoderm. Derivatives of ectoderm such as squamous epithelium and mature skin appendages like hair is not seen in this case which helps in differentiating dermoid cyst from eccrine hydrocystoma.

Eccrine hydrocystoma, Apocrine hydrocystoma and lacrimal gland cyst are commonly seen on eye lid and generally presents in middle to elderly age. EH is more commonly seen in lower eyelid while AH and lacrimal gland cyst commonly seen in upper eyelid. All three presents as bluish unilocular translucent papule or cystic lesion, having clear to brownish fluid, while in this case is cyst was multiloculated and presented in upper eyelid. AH has dual layer- outer myoepithelial cells and inner columnar cells with decapitation secretions and apical snouts which are pathognomic feature while EH has bilayer cuboidal cells without any apical snouting and decapitation secretion. Lacrimal gland cyst and similar findings, however in this case presence of goblet cells and inner eosinophilic Layer differentiates it from Lacrimal gland cyst. Most eccrine hydrocystomas are solitary and surgical treatment of choice is complete excision with an intact cyst. Simple needle puncture is generally not recommended as recurrences are common and may result in infections but may be considered if patient is unwilling for complete excision. Cryotherapy, electrodesiccation of the cyst wall, carbon dioxide laser ablation has also been reported in cases of recurrent Eccrine cyst. (Eslami et al., 2020; Singh et al., 2005).

Treatment of the underlying condition may result in a decrease in the size and quantity of the lesions in cases where the eccrine hydrocystoma is linked to a systemic disorder, such as Graves' disease.

CONCLUSION

Majority of eccrine hydrocystomas usually present on lower eyelid and in middle-aged to old aged patients while in this case the lesion presented on upper eyelid, away from lid margins and in the paediatric age which is rare and usually derails the clinical diagnosis, however the histopathological examination is essential for the accurate diagnosis.

Orbital eccrine hydrocystomas should be considered in the differential diagnosis of orbital cystic masses in the pediatric age group. It is managed by complete excision and histopathological confirmation. Prompt management is required in case of paediatric age group as it can develop ptosis and amblyopia. (Al Rasheed & AlSamnan, 2019)

REFERENCES

1. Al Rasheed, R., & AlSamnan, M. (2019). Congenital giant orbital eccrine hidrocystoma. *American Journal of Ophthalmology Case Reports*, 16, 100570. <https://doi.org/10.1016/j.ajoc.2019.100570>
2. Alfadley, A., Al Aboud, K., Tulba, A., & Mourad, M. M. (2001). Multiple eccrine hidrocystomas of the face. *International Journal of Dermatology*, 40(2), 125–129. <https://doi.org/10.1046/j.1365-4362.2001.01126.x>
3. Eslami, F., Rafi, A. M., & Basir, H. R. G. (2020). A Case Report of Eccrine Hidrocystoma. *سینا، این بالینی پزشکی* 26(4), 247–251.
4. Hodge, B. D., Sanvictores, T., & Brodell, R. T. (2026). *Anatomy, Skin Sweat Glands*(Archived). In StatPearls. StatPearls Publishing. <http://www.ncbi.nlm.nih.gov/books/NBK482278/>
5. Singh, A. D., McCloskey, L., Parsons, M. A., & Slater, D. N. (2005). Eccrine hidrocystoma of the eyelid. *Eye*, 19(1), 77–79. <https://doi.org/10.1038/sj.eye.6701404>